

Prevalence of oral manifestations of hypophosphatemic rickets in patients treated in a Peruvian Pediatric Hospital.

Prevalencia de manifestaciones bucales del raquitismo hipofosfatémico de pacientes atendidos en un Hospital pediátrico Peruano.

Janet Ofelia Guevara-Canales.¹

Nathali Cardenas-Zuñiga.¹

Miguel Chavez-Pastor.[†]

Milana Trubnykova.²

Rafael Morales-Vadillo.¹

Affiliations:

¹Facultad de Odontología de la Universidad de San Martín de Porres (FO-USMP), Lima, Perú.

²Servicio de Genética y Errores Innatos del Metabolismo, Instituto Nacional de Salud del Niño (INSN), Lima, Perú.

Corresponding author: Janet-Ofelia Guevara-Canales. Calle Manuel Scorza # 102, Depto 201, San Borja, Lima-41, Lima, Perú. **E-mail:** janetguevara7@hotmail.com

Receipt : 03/20/2020 **Revised:** 01/29/2020

Acceptance: 10/03/2020

Abstract: Objective: To describe the prevalence of oral manifestations of hypophosphatemic rickets in patients treated in a Peruvian referral pediatric hospital during the years 2012-2016. **Material and methods:** An observational, descriptive, retrospective, cross-sectional study was carried out. The sample consisted of patients diagnosed with hypophosphatemic rickets who attended the outpatient clinic of the Stomatology Service and the Genetics Service of the National Institute of Child Health (INSN), Lima, Peru, between the years 2012-2016. The research project was assessed and approved by the Research Ethics Committee of the Health Service. Medical records stored in a database of the health institution with the Code CIE E83.3, which corresponds to the diagnosis of Hypophosphatemic Rickets, were requested for the study. **Results:** Fifteen children received health care, of which only 10 were treated at the Stomatology Service. The distribution of the data was obtained from these 10 patients according to the proposed objective. A higher frequency of gingival lesions was found at the soft tissue level (41.18%); at the bone tissue level, only one case of dentigerous cyst was observed; and at the dental level, 90% of the patients had dental caries. **Conclusion:** The most frequent oral manifestations of hypophosphatemic rickets in pediatric patients treated at the National Institute of Child Health (2012-2016) were gingivitis and dental caries.

Keywords: Oral Medicine; Rickets, Hypophosphatemic; Vitamin D; Dental Enamel Hypoplasia; Child Health.

Resumen: Objetivo: Describir la prevalencia de las manifestaciones bucales del raquitismo hipofosfatémico de pacientes atendidos en un hospital pediátrico de referencia peruano durante los años 2012-2016. **Material y Métodos:** Se realizó un estudio tipo observacional, descriptivo, retrospectivo, transversal. Para la selección de la muestra se consideró a los pacientes que acudieron a la consulta externa del Servicio de Odontoestomatología y el Servicio de Genética del Instituto Nacional de Salud del Niño, Lima, Perú; en el periodo comprendido entre los años 2012-2016 y que presentaron como diagnóstico Raquitismo Hipofosfatémico. El proyecto de investigación fue evaluado por un Comité de Ética en Investigación del servicio de salud. Se solicitaron las historias clínicas consignadas en una base de datos de la institución de salud con el Código CIE E83.3, que corresponde a este diagnóstico. **Resultados:** Fueron atendidos 15 niños, de los cuales solo 10 fueron tratados en el Servicio Odontoestomatología;

Cite as: Guevara-Canales JO, Cardenas-Zuñiga N, Chavez-Pastor M, Trubnykova M & Morales-Vadillo R.

Prevalence of oral manifestations of hypophosphatemic rickets in patients treated in a Peruvian Pediatric Hospital. J Oral Res 2020; 9(5):383-391.

Doi:10.17126/joralres.2020.079

siendo de estos 10 pacientes la distribución de los datos obtenidos según el objetivo propuesto. Se encontró mayor frecuencia de lesiones a nivel de tejido blando de gingivitis con 41.18%, a nivel de tejido óseo solo se presentó un caso de quiste dentífero; y a nivel de tejido dental el 90% de los pacientes presentó caries dental. **Conclusión:** Las

manifestaciones bucales más frecuentes del raquitismo hipofosfatémico de pacientes pediátricos atendidos en el Instituto Nacional de Salud del Niño (2012-2016), fueron la gingivitis y caries dental.

Palabra Clave: Medicina Oral; Raquitismo Hipofosfatémico; Vitamina D; Hipoplasia del Esmalte Dental; Salud del Niño.

INTRODUCTION.

Definition

The disease, first named refractory rickets by McCune¹ in 1935, occurred in patients who did not show improvement after being treated with physiological doses of vitamin D. Two years later, Albright *et al.*,² described this condition as hypophosphatemic rickets (HR), a disorder linked to the X chromosome.³ This pathology leads to a metabolic disturbance of calcium and phosphate (hypophosphatemia) which results in abnormalities (defective calcification) in mineralized tissues such as bones and teeth.⁴⁻⁶ Some studies report an estimated incidence of 1:20,000 people.³

Bone metabolic alterations cause specific clinical and systemic characteristics, which can vary from person to person due to several factors, such as the age of development of the disease, family history, the degree of hypophosphatemia, and the time of initiation of therapy.⁷ The clinical manifestations of HR at the maxillofacial level are individual and, in some cases, go unnoticed due to the progression of its systemic manifestations.

Most studies on this pathology focus only on its systemic aspects; the manifestations or consequences at the maxillofacial level are covered only by case reports. For this reason, the aim of this study was to describe the population with this disease in a reference institution such as the National Institute of Child Health (INSN, for its acronym in Spanish), located in the district of Breña, in Lima, Peru, from the oral and maxillofacial manifestations at the levels of soft tissue, bone tissue, and dental tissue according to age and sex.

General classification of rickets

Rickets is classified into two main types: calcipenic and phosphopenic; the former involves a deficit due to a deficiency of vitamin D resulting from insufficient intestinal absorption of calcium, and the latter, a deficit of phosphate due to a metabolic disorder.⁸ These two large groups are in turn divided into

- 1) Deficiency or Acquired Rickets and
- 2) Resistant or Hereditary Rickets.⁹

There are many subtypes of hereditary rickets,⁹ described on a genetic basis which can be subdivided into:

- Primary: vitamin D-dependent rickets, which is a genetic disease caused by a congenital error in the metabolism of vitamin D.
- Secondary: rickets resistant to vitamin D, the most common subtype, to which HR belongs.

Synonyms

HR is also known as vitamin D-resistant hypophosphatemic rickets, vitamin D-resistant rickets, familial or hereditary hypophosphatemic rickets, phosphate diabetes, X-linked hypophosphatemia, or refractory rickets.¹⁰

Pathophysiology

The regulation of the systemic phosphorus balance is carried out through the kidneys and by intestinal absorption.^{11,12} To maintain this balance, the amount of phosphate must be similar to the quantity excreted, an action that is coordinated by hormones and factors such as fibroblast growth factor-23 (FGF-23) and coordinated by the active form of vitamin D.¹¹ When an alteration occurs in this systemic phosphorus balance, pathologies such as renal loss of phosphates may also occur, and HR may come as a result of the genetic mutation of the phosphate regulator gene PHEX, an encoded endopeptidase located on the X chromosome.^{13,14}

Systemic manifestations

The most common clinical manifestation of HR is delayed body growth and short height.¹⁵ Affected patients usually do not present hypotonia or muscle weakness, tetany, or seizures, which are common manifestations in children with vitamin D-dependent or resistant rickets.¹⁶ In some cases, joint and bone pain¹⁷ and fractures¹³ may occur; in addition, premature fusion of cranial sutures leading to dolichocephaly and/or craniosynostosis may also be prevalent, which

may result in increased intracranial pressure, Chiari type I malformation, syringomyelia, papillary edema or neurological signs,^{18,19} and even hearing loss.¹³

Implications at the oral and maxillofacial levels

Harris *et al.*,²⁰ issued the first reports of dental manifestations that affect the patient's quality of life.²¹ At the oral and maxillofacial levels, dental alterations can occur in both dentitions, but more frequently in the primary dentition;²² for example, the lack of cement. Other reported oral manifestations include the following.

Periodontal disease:

The lack of cement does not allow adequate attachment of the tooth to the periodontal ligament through Sharpey's fibers. Consequently, patients can suffer from mild periodontal disease such as gingivitis in 10.9% of the cases,²³ to rapid destruction and early exfoliation of primary and permanent dentition.²⁴

Enamel hypoplasia:

Enamel hypoplasia²⁵ has been reported to range from 42.1%²³ to 57.1%²⁶ among patients with HR. Although some authors have reported the presence of normal²⁰ but thin enamel, hypoplastic enamel has been associated with late initiation of treatment.²⁷

Defects at the dentin level:

These are dentinal defects characterized by hypocalcified dentin in both dentitions.^{25,28} Although it is reported that the function of the odontoblast cell is normal, dental mineralization is not adequate due to hypophosphatemia that leads to dysplastic dentin with little mineralization, with areas of interglobular dentin,²⁵ and irregular dentin tubules.²⁹ Souza *et al.*,²⁶ reported this in 14.3% of HR patients.

Dental caries:

A high prevalence of dental caries have been documented in HR patients, with a study reporting 47.7%.²³ Some authors suggest that the placement of a metal crown on primary teeth could prevent caries lesions and pulp alterations.³⁰

Taurodontism:

Several studies describe the presence of enlarged pulp chambers with horns that extend to the dentin-enamel junction in patients with this pathology.^{3,25,28,29} This lesion may account for 15.8% of dental lesions in patients with HR.²³

Dental abscesses:

Spontaneous presence of abscess-type lesions without dependence on carious lesions or history of

trauma.^{5,28,29} Some authors suggest that this condition may be due to the entry of bacteria through enamel microfractures that extend to pulp and lead to tissue necrosis.²⁹ Tooth extraction is indicated as a radical treatment for this manifestation if endodontic treatment fails.³¹

Delayed dental development:

It occurs in severe forms of HR.²⁹ This indicator is reported, for example, in a study in which authors describe three cases of patients who before receiving HR treatment had unerupted primary incisors,²⁷ and another study reporting a 47.7% delay in tooth eruption.²³

Occlusion alteration:

According to Souza *et al.*,²⁶ defective occlusion may account for up to 85.7% of the cases.

Fractures:

Both dental and maxillary.²⁹

Maxillary growth:

Growth retardation has been reported in the upper and lower jaws.³²

Treatment

The treatment of hypophosphatemia varies depending on the stage and the classification. In most cases, treatment focuses on bone deformities such as stretching and growth of the legs,³³ in addition to systemic implications. Current therapy with phosphate supplements and active vitamin D analogs may partially correct growth and mineralization; however, this treatment requires an appropriate balance between the benefits derived from treatment and the potential risks,³³ such as abnormal serum phosphate level,³⁴ is achieved.

At the dental and maxillofacial level, treatment only moderately prevents dental and periodontal lesions³⁵ since clinical implications at the maxillofacial level may persist despite treatment.²⁶ Substances that act as protective agents are suggested as options, evaluating the risk of caries by remineralizing non-cavitated lesions,³⁶ with a fluoride toothpaste at least twice a day or application of fluoride varnish every 6 months.³⁷ In severe cases, an option is oral rehabilitation with the use of dental implants, although with a limited degree of success.¹⁴

Due to potential implications at the oral and maxillofacial level, the present research aims to describe the prevalence of oral manifestations of hypophosphatemic rickets in patients treated in a Peruvian referral pediatric

hospital during the years 2012-2016. The objective is to answer the question: What are the oral manifestations in patients diagnosed with hypophosphatemic rickets reported by the INSN?

MATERIALS AND METHODS.

Methodological Design

Observational, descriptive, retrospective, and cross-sectional study.

Sample Design

The population consisted of the medical records of patients treated at the INSN. The sample consisted of all patients with a diagnosis of HR (performed by physicians specialized in genetics and endocrinology and confirmed by laboratory tests), who attended the outpatient consultation of the Stomatology Service and Genetics Service from their birth to 12 years of age, during the period 2012-2016. As inclusion criteria, patients had to have a complete medical history with records of complete oral and maxillofacial characteristics such as odontogram and periapical radiographs. Patients who presented any other systemic disease such as diabetes or neoplastic diseases were excluded from the study.

Data Collection Techniques

Permits and authorizations: The research project was granted the authorization of the Research Institute of the School of Dentistry of Universidad de San Martín de Porres (FO-USMP). Regarding the authorization of the INSN, the research project was sent for final approval to the University Teaching Area, where it was evaluated and approved by the Ethics Committee.

Collecting the clinical records

The list of the clinical records of patients with a diagnosis of HR treated between 2012 and 2016 was obtained from the Statistics Department of the INSN. This was done through the CIE Code E83.3, which corresponds to the registration code for this diagnosis.

Review of medical records

A restricted number of medical records provided by the INSN Archives Department were reviewed per day considering the inclusion and exclusion criteria. Patients had been treated in the outpatient consultation at the Genetics and Stomatology Service. The data of interest from the selected medical records were recorded in a data collection sheet.

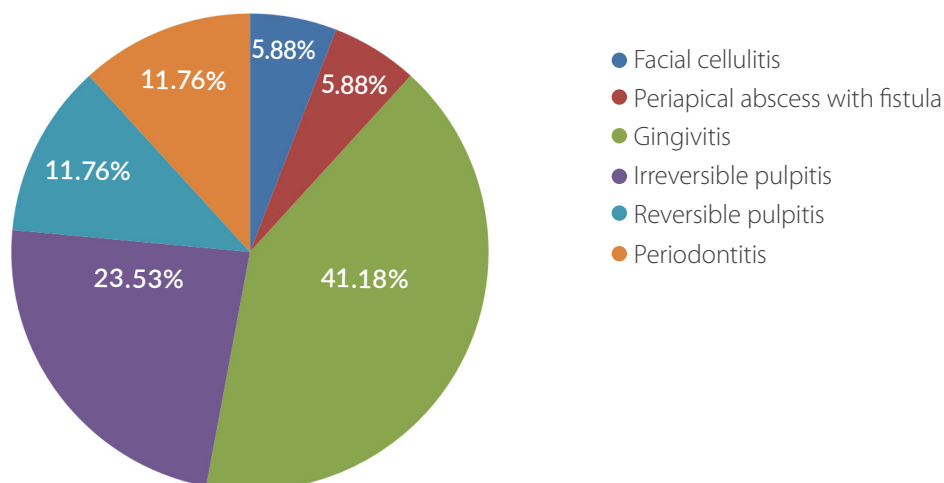
Statistical Techniques for Information Processing

Subsequently, the data were digitized into a database using Microsoft Office Excel, where the respective tables and graphs were drawn up according to the objectives of the study.

Ethical Aspects

The research project was evaluated by a Research Project Review Committee (ACT N°008-2017-CRPI/INVE-FO-USMP) and by a Research Ethics Committee (ACT N°001-2017-CEI/INVE-FO-USMP) of the FO-USMP. In addition, the research project was also evaluated by the Ethics Committee of the INSN (FORM N°0302-2017-CEI-INSN). When collecting the data, only the identification number of the medical records was registered, protecting the anonymity of the patient. Only the main researcher and her assistant were given access to these data.

Figure 1. Oral manifestations of hypophosphatemic rickets affecting soft tissue.



RESULTS.

According to the data obtained in the INSN, regarding the prevalence of HR between the years 2012-2016, 15 children had been treated, of which only 10 met the inclusion and exclusion criteria of this study. Of these, 10 cases, 60% were male, who accounted for 70.3% of the lesions found. The prevalence of the oral and maxillofacial manifestations of these 10 patients is presented in a summary table (Table 1), where the sex

and age range of each patient are detailed. Regarding the manifestation at the soft tissue level, it was found that gingivitis was the most prevalent condition with 41.18%, followed by irreversible pulpitis (23.53%). (Figure 1).

Concerning the prevalence of oral manifestations at the bone tissue level, dentigerous cyst was the only pathology found. Regarding the prevalence of manifestations in dental tissue, the most prevalent was

Figure 2. Oral manifestations of hypophosphatemic rickets affecting dental tissue.

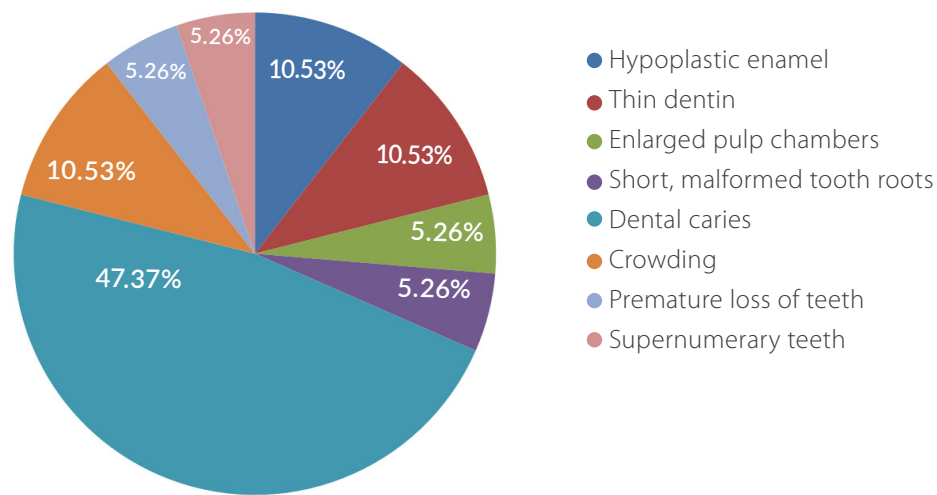


Table 1. Summary of the frequency of cases according to all the variables evaluated.

No.	Age in years			Sex	Lesions affecting						Dental tissue								
	0-6	7-9	10+		Soft tissue			Bone tissue	Dental tissue										
					Facial cellulitis	Periapical abscess with fistula	Gingivitis	Irreversible pulpitis	Reversible pulpitis	Periodontitis	Dentigerous cyst	Hypoplastic enamel	Thin dentin	Enlarged pulp chambers	Short, malformed roots	Dental caries	Crowding	Premature loss of teeth	Supernumerary teeth
1	0	0	1	M	0	0	0	1	0	1	0	0	0	0	0	0	0	1	0
2	0	0	1	M	0	0	1	0	0	1	0	0	0	0	0	1	0	0	0
3	1	0	0	F	0	0	1	0	0	0	0	0	0	0	0	1	0	0	0
4	0	0	1	M	0	0	1	0	0	0	0	0	0	0	0	1	0	0	0
5	1	0	0	M	0	0	0	1	1	0	0	1	1	0	0	1	0	0	0
6	0	1	0	M	1	0	1	0	0	0	1	1	1	1	1	1	0	0	1
7	0	0	1	F	0	0	1	0	0	0	0	0	0	0	0	1	1	0	0
8	0	1	0	F	0	1	0	1	1	0	0	0	0	0	0	1	0	0	0
9	1	0	0	M	0	0	1	1	0	0	0	0	0	0	0	1	1	0	0
10	0	0	1	F	0	0	1	0	0	0	0	0	0	0	0	1	0	0	0

F: Female. M: Male.

dental caries (47.37%). Other manifestations observed were enlarged pulp chambers and supernumerary teeth (Figure 2).

DISCUSSION.

Between 2012 and 2016, a total of 15 HR patients were treated at the INSN, of which only 10 were referred to the Stomatology Service; consequently, these were the ones included in the present study. This information corresponds to a study carried out in the same institution between 2002 and 2011, where researchers found 22 patients with this disease, but dental evaluations were not necessarily carried out in all the cases.³⁸

When determining the prevalence of oral manifestations of HR in pediatric patients treated at the INSN, according to its location in soft tissue, six different lesions were found, among them is periapical abscess. In this study, only one patient presented periapical abscess with a fistula at the level of oral soft tissue, similar to that described by Souza *et al.*,²⁶ who also found a single case with dental abscess of the 14 reported with HR.

This finding is different from what has been reported in most studies,³⁹ in which the presence of a fistula is highly prevalent, as suggested by Sakihara *et al.*,³⁸ in a study carried out in Peru, where they presented a case of a 4-year-old boy with multiple dental abscesses. Most of the studies show a significant relationship between HR and the presence of multiple periapical abscesses in caries-free teeth with no history of trauma,⁴⁰ as documented by Baroncelli *et al.*,³⁵ who reported that 67% of patients had a history of spontaneous fistulas as a consequence of periapical abscesses that occurred in the absence of dental caries or a history of trauma. Having found only one case with periapical abscess may be due to the fact that only a limited number of these patients are referred to specialized oral cavity evaluation. It is pertinent to emphasize that six lesions were found at the pulp level in agreement with the study carried by Lee *et al.*⁴¹

This may be due to the invasion of bacteria caused by poor mineralization of the dental hard tissue. At the bone tissue level, most studies report cases of osteomyelitis or delayed growth of the maxilla and mandible.³² However, in the present study, there were no patients with a bone-level lesion, except for a cystic lesion of dentigerous cyst origin. This type of

lesion has not been referenced in other original studies except for an isolated clinical case described by Batra *et al.*²² Other bone characteristics that can occur at the periapical bone level is the partial or total absence of the hard sheet.⁴²

The findings at the dental tissue level, according to the literature, are mainly attributed to enamel hypoplasia at the incisal²⁹ or cusps²⁰ levels. Other studies report a delay in the eruption of teeth from both dentitions.⁴² In the present research, 20% of the cases presented enamel hypoplasia, which was the only lesion observed at the dental enamel level. This coincides with the first reports of dental injuries in patients with HR.²⁰

Regarding the enlargement of the chambers and root canals, only one case was found, while in most studies a higher frequency has been reported,²⁹ both in primary and permanent dentition;³⁵ Souza *et al.*,²⁶ reported this condition in 42.9% of the cases. In the present study, a case of a supernumerary tooth was observed in an 8-year-old boy, which coincides with a case described by Thakur.⁴³ Regarding dental caries, this was the pathology with the highest frequency, similar to what has been reported in other studies, such as the one conducted by Rabbani *et al.*²³

CONCLUSION.

The most frequent oral manifestations of hypophosphatemic rickets in pediatric patients treated at the National Institute of Child Health (2012-2016) were gingivitis in males and dental caries, which occurred in all except one of the patients evaluated in that institution. It must be emphasized that in this type of disease, as in all systemic diseases, diagnosis, control and monitoring of dental conditions must be carried out. Oral and maxillofacial care protocols should be performed, and research carried out to include all the possible causes to avoid potential bias due to the small number of patients affected by this type of condition.

Conflict of interests: There are no conflicts of interest of the researchers with the possible applications or effects of the results of this research.

Ethics approval: The research project was evaluated by a Research Projects Review Committee (ACTA N°008-2017-CRPI/INVE-FO-USMP) and by a Research Ethics Committee (ACTA N°001-2017-CEI/INVE-FO-USMP) of FO-USMP. In addition, the research project was also evaluated by the Ethics Committee of the INSN (OFICIO N°0302-2017-CEI-INSN).

Funding: Selffunding.

Authors' contributions: JOGC: Study design, data collection, writing of the manuscript, final approval of the manuscript. NCZ: Study design, data collection,

review of the final version of the manuscript. MCP: Study design, data collection, writing of the manuscript, final approval of the manuscript. MT: Study design, data collection, writing of the manuscript, final approval of the manuscript. RMV: Study design, statistical analysis and interpretation of the results, review of the final version of the manuscript, final approval of the manuscript.

Acknowledgements: Dr. Miguel Chávez-Pastor sadly passed away shortly before this manuscript went to press. We are saddened to report the premature death of our colleague and dedicate the work presented in this paper to his memory.

REFERENCES.

1. McCune DV. Refractory rickets. *J Pediatr*. 1935;6:872-3.
2. Albright F, Butler AM, Bloomberg E. Rickets resistant to vitamin D therapy. *Am J Dis Child*. 1937;54:529-47.
3. Gattineni J, Baum M. Genetic disorders of phosphate regulation. *Pediatr Nephrol*. 2012;27:1477-87.
4. Stratakis CA, Mitsiades NS, Sun D, Chrousos GP, O'Connell A. Recurring oral giant cell lesion in a child with X-linked hypophosphatemic rickets: clinical manifestation of occult parathyroidism? *J Pediatr*. 1995;127:444-6.
5. Goodman JR, Gelbier MJ, Bennett JH, Winter GB. Dental problems associated with hypophosphatemic vitamin D resistant rickets. *Int J Paediatr Dent*. 1998;8:19-28.
6. Shroff D, McWhorter A. Evaluation of aggressive pulp therapy in a population of vitamin D-resistant rickets patients: a follow-up of 4 cases. *Pediatr Dent*. 2002;24:347-9.
7. Malloy PJ, Pike JW, Feldman D. The vitamin D receptor and the syndrome of hereditary 1, 25-dihydroxyvitamin D-resistant rickets. *Endocr Rev*. 1999;20:156-88.
8. Jagtap VS, Sarathi V, Lila AR, Bandgar T, Menon P, Shah NS. Hypophosphatemic rickets. *Indian J Endocrinol Metab*. 2012;16(2):177-82.
9. De la Calle T. Raquitismo carencial. Raquitismos resistentes. *Pediatr Integral*. 2015;19(7):477-487.
10. Velásquez-Jones L, Medeiros-Domingo M. Raquitismos hipofosfatémicos hereditarios. *Bol Med Hosp Infant Mex*. 2013;70(6):421-31.
11. Velásquez JL. Alteraciones Hidroelectrolíticas en Pediatría. México: Editorial Prado; 2010.
12. Santos F, Fuente R, Mejia N, Mantecon L, Gil-Peña H, Ordoñez FA. Hypophosphatemia and growth. *Pediatr Nephrol*. 2013;28:595-603.
13. Linglart A, Biosse-Duplan M, Briot K, Chaussain C, Esterle L, Guillaume-Czitrom S, Kamenicky P, Nevoux J, Prié D, Rothenbuhler A, Wicart P, Harvengt P. Therapeutic management of hypophosphatemic rickets from infancy to adulthood. *Endocr Connect*. 2014;3(1):R13-30.
14. James M, Roudsari RV. Prosthetic rehabilitation of a patient with X-linked hypophosphatemia using dental implants: a case report and review of the literature. *Int J Implant Dent*. 2019;5(1):15.
15. Fuente R, Gil-Peña H, Claramunt-Taberner D, Hernández O, Fernández-Iglesias A, Alonso-Durán L, Rodríguez-Rubio E, Santos F. X-linked hypophosphatemia and growth. *Rev Endocr Metab Disord*. 2017;18(1):107-115.
16. Velásquez JL, Gordillo PG. Raquitismo dependiente de vitamina D tipo I: tratamiento con 1,25-dihidroxitamina D. *Bol Med Hosp Infant Mex*. 1984;41:36-40.
17. Rothenbuhler A, Schnabel D, Högler W, Linglart A. Diagnosis, treatment-monitoring and follow-up of children and adolescents with X-linked hypophosphatemia (XLH). *Metabolism*. 2020;103S:153892.
18. Rothenbuhler A, Fadel N, Debza Y, Bacchetta J, Diallo MT, Adamsbaum C, Linglart A, Di Rocco F. High Incidence of Cranial Synostosis and Chiari I Malformation in Children With X-Linked Hypophosphatemic Rickets (XLHR). *J Bone Miner Res*. 2019;34(3):490-496.
19. Vega RA, Opalak C, Harshbarger RJ, Fearon JA, Ritter AM, Collins JJ, Rhodes JL. Hypophosphatemic rickets and craniosynostosis: a multicenter case series. *J Neurosurg Pediatr*. 2016;17(6):694-700.
20. Harris R, Sullivan HR. Dental sequelae in deciduous dentition in vitamin D resistant rickets. *Aust Dent J*. 1960;5:200-3.
21. Hanisch M, Bohner L, Sabandal MMI, Kleinheinz J, Jung S. Oral symptoms and oral health-related quality of life of individuals with x-linked hypophosphatemia. *Head Face Med*. 2019;15(1):8.
22. Batra P, Tejani Z, Mars M. X-linked hypophosphatemia: dental and histologic findings. *J Can Dent Assoc*. 2006;72(1):69-72.
23. Rabbani A, Rahmani P, Ziaee V, Ghodoosi S. Dental problems in hypophosphatemic rickets, a cross sectional study. *Iran J Pediatr*. 2012;22(4):531-4.
24. Sollecito TP, Sullivan KE, Pinto A, Stewart J, Korostoff J. Systemic conditions associated with periodontitis in childhood and adolescence. A review of diagnostic possibilities. *Med Oral Patol Oral Cir Bucal*. 2005;10(2):142-50.
25. Murayama T, Iwatsubo R, Akiyama S, Amano A, Morisaki I. Familial hypophosphatemic vitamin D-resistant rickets: dental findings and histologic study of teeth. *Oral Surg Oral Med Oral Pathol Oral Radiol Endod*. 2000;90:310-6.
26. Souza MA, Soares Junior LA, Santos MA, Vaisbich MH. Dental abnormalities and oral health in patients with Hypophosphatemic rickets. *Clinics (Sao Paulo)*. 2010;65(10):1023-6.
27. Hanna AE, Sanjad S, Andary R, Nemer G, Ghafari JG. Tooth Development Associated with Mutations in Hereditary Vitamin D-Resistant Rickets. *JDR Clin Trans Res*. 2018;3(1):28-34.
28. Ozkan S, Uçok Z, Alagol F. Dental manifestations of familial hypophosphatemic vitamin-D-resistant rickets. *ASDC J Dent Child*. 1984;51:448-50.
29. Pereira CM, de Andrade CR, Vargas PA, Coletta RD, de Almeida OP, Lopes MA. Dental alterations associated with Xlinked hypophosphatemic rickets. *J Endod*. 2004;30:241-45.
30. Yasufuku Y, Kohno N, Tsutsumi N, Ooshima T, Sobue S, Murakami Y, Ikari H. Dental management of familial hypophosphatemic vitamin D-resistant rickets: report of case. *ASDC J Dent Child*. 1983;50(4):300-4.
31. Herbert FL. Hereditary hypophosphatemia rickets: an important awareness for dentists. *ASDC J Dent Child*. 1986;53:223-6.
32. Shafer W, Hine M, Levy B. Oral pathology. 3rd ed. Philadelphia: WB Saunders, 1974:593-5.
33. Lecoq AL, Brandi ML, Linglart A, Kamenický P. Management of X-linked hypophosphatemia in adults. *Metabolism*. 2020;103S:154049.
34. Lambert AS, Zhukouskaya V, Rothenbuhler A, Linglart A. X-linked hypophosphatemia: Management and treatment prospects. *Joint Bone Spine*. 2019;86(6):731-738.
35. Baroncelli GI, Angiolini M, Ninni E, Galli V, Saggese R, Giuca MR. Prevalence and pathogenesis of dental and periodontal lesions in children with X-linked hypophosphatemic rickets. *Eur J Paediatr Dent*. 2006;7(2):61-6.
36. Tyas MJ, Anusavice KJ, Frencken JE, Mount GJ. Minimal intervention dentistry--a review. *FDI Commission Project 1-97*. *Int Dent J*. 2000;50(1):1-12.
37. Featherstone JDB, Alston P, Chaffee BW, Rechmann P. Caries Management by Risk Assessment (CAMBRA): An Update for Use in Clinical Practice for Patients Aged 6 Through Adult. *J Calif Dent Assoc*. 2019;47(1):16-25.

38. Sakihara GA, Choque TH, Mendoza BA, López CV, Pimentel KG, Encinas AM, Ancieta ZA. Raquitismo Renal Hipofosfatémico Experiencia en 10 Años. Rev Peru Pediatr. 2014;67(1):22-30.
39. Godina G, Belmont F. Características dentales del raquitismo hipofosfatémico. Reporte de un caso. Rev Odonto Mexic. 2013;17(2):101-8.
40. Beltes C, Zachou E. Endodontic management in a patient with vitamin D-resistant rickets. J Endod. 2012; 38:255-258.
41. Lee BN, Jung HY, Chang HS, Hwang YC, Oh WM. Dental management of patients with X-linked hypophosphatemia. Restor Dent Endod. 2017;42(2):146-151.
42. Koehne T, Marshall RP, Jeschke A, Kahl-Nieke B, Schinke T, Amling M. Osteopetrosis, osteopetrorickets and hypophosphatemic rickets differentially affect dentin and enamel mineralization. Bone. 2013;53:25-33.
43. Thakur M. Familial Vitamin D-dependent rickets Type 2A: A report of two cases with alopecia and oral manifestations. J Oral Maxillofac Pathol. 2019;23(Suppl1):130-133.

Laser Doppler Flowmetry as a method of analysis for the evaluation of chemo - induced oral mucositis: A pilot study.

Flujometría por láser Doppler como método de análisis para la evaluación de la mucositis oral inducida por quimioterapia: Un estudio piloto.

Emanoele Silva.¹
Raquel Caminha.¹
Marcelo Zanda.²
Paulo Santos.¹

Affiliations:

¹Department of Surgery, Stomatology, Pathology and Radiology, Bauru School of Dentistry, University of São Paulo, Bauru, Brazil.

²Center Research Clinical, University of São Paulo, Bauru, Brazil.

Corresponding author: Paulo Santos. Alameda Octávio Pinheiro Brisola, 9-75, Bauru, São Paulo, Brazil. **Phone:** (55-14) 3226-6113. **E-mail:** paulosss@fob.usp.br

Receipt : xx/xx/2019 **Revised:** xx/xx/2020
Acceptance: xx/xx/2020

Abstract: Background: Oral mucositis (OM) is an inflammation of the oral mucosa due to cancer therapy that compromises the patient's quality of life. Laser Doppler flowmetry (LDF) is a non-invasive method to monitor microvascular blood flow (BF) in real-time. **Purpose:** Develop a method to evaluate BF in the genian region cheek in patients undergoing chemotherapy by LDF and compare the degrees of OM and pain with evaluation of BF. **Material and methods:** Evaluation of OM was performed using the World Health Organization (WHO) and Oral Mucositis Assessment Scale (OMAS) scales and the visual analog scale for pain evaluation. For flowmetry analysis, a laser Doppler flowmeter (moorVMSTM™, 780 nm wavelength and VP3 probe), fixed by an acrylic resin support was used; VP3 probe was positioned on the genian region and the patient's head was stabilized with a neck pillow for an accurate measurement. The Wilcoxon test was used to compare the flowmetry results at the studied times. The Pearson correlation coefficient was used to evaluate relationships between BF and the WHO, OMAS and visual analog scales. **Results:** Eleven patients of both sexes, aged between 30 and 78 years, with OM were included. An increase in cutaneous BF was observed at the initial times of OM, with progressive reduction during the chemotherapy cycle. There was a statistical difference ($p < 0.05$) between time point T0 (first consultation) and time point T6 (last consultation). **Conclusion:** The method developed in this pilot study is effective, reliable, and reproducible, and allows the evaluation of BF dynamics in the genian region using LDF of patients undergoing chemotherapy at risk of developing OM.

Keywords: Antineoplastic agents; neoplasms; stomatitis; laser-doppler flowmetry; microcirculation; mouth mucosa.

Cite as: Silva E, Caminha R, Zanda M & Santos P.

Laser Doppler Flowmetry as a method of analysis for the evaluation of chemo-induced oral mucositis: A pilot study.

J Oral Res 2020; 9(5):xxx-xxx.

Doi:10.17126/joralres.2020.080

Resumen: Antecedentes: La mucositis oral (MO) es una inflamación de la mucosa oral debido a la terapia del cáncer, que compromete la calidad de vida del paciente. La flujometría láser Doppler (FLD) es un método no invasivo para monitorear el flujo sanguíneo microvascular (FS) en tiempo real. **Objetivo:** Desarrollar un método para evaluar la FS en la mejilla de la región geniana en pacientes sometidos a quimioterapia por FLD y comparar los grados de MO