

## Non-invasive treatment of an acute sinusitis after open maxillary sinus floor augmentation with simultaneous bone graft and implant placement. Case Report.

Erick Fernández.<sup>1</sup>

**Affiliations:** <sup>1</sup>Private practice in Gran Canaria, Spain.

**Corresponding author:** Erick Fernández. Calle Venegas, 39, 35003 Las Palmas de Gran Canaria, Spain. Phone: (+34) 8281 25948. E-mail: Kcire008@yahoo.es.

**Receipt:** 02/06/2017 **Revised:** 02/13/2017  
**Acceptance:** 02/27/2017 **Online:** 02/27/2017

**Conflict of interests:** None.

**Ethics approval:** Patient signed the informed consent.

**Funding:** None.

**Authors' contributions:** The author carried out the entire case report.

**Acknowledgements:** None.

**Cite as:** Fernández E. Non-invasive treatment of an acute sinusitis after open maxillary sinus floor augmentation with simultaneous bone graft and implant placement. Case Report. J Oral Res 2017; 6(2): 46-49. doi:10.17126/joralres.2017.014

**Abstract:** Currently, the maxillary sinus floor augmentation technique is one of the most common procedures used in implantology. Despite being a straightforward technique, epistaxis, perforation of the Schneiderian membrane and acute sinusitis. Although many theories have been proposed as to the etiology of sinusitis, the majority of cases are due to idiopathic causes. Its treatment can often be very complex and traumatic for the patient. It normally involves antibiotic treatment combined with surgical or endoscopic procedures. The following case describes the full resolution of this disorder with abundant sinus rinsing with salt water and combined treatment of antibiotics and mucolytics without the need for removal of the implant or bone graft. Despite the disorder in this case being eradicated with a different approach combining antibiotics, mucolytics and sinus rinses, it is concluded that more studies are necessary before it is established as a definitive treatment procedure.

**Keywords:** Maxillary sinusitis; sinus floor augmentation; dental implant.

### INTRODUCTION.

Currently, the maxillary sinus floor augmentation technique is one of the most common procedures used in implantology. This is due to the need to rehabilitate the posterior areas of the maxilla which are often atrophied due to the prevalence of the cancellous bone type IV and to the dental extractions which cause a rapid vertical and horizontal reabsorption, which in many cases is accompanied with an increase in the pneumatisation of the sinus in these areas.<sup>1-7</sup>

This technique was described for the first time by Boyne et al in 1965, and became popular in the eighties. They used an approach on the sinus employing the Caldwell-Luc operation technique. Summers then popularised the crestal approach accompanied by the use of osteotomies and bone grafts, considering this procedure to be less invasive.<sup>1,4,8</sup>

Despite sinus augmentation being a straightforward technique, it can still lead to complications such as the spread of graft material into the sinus cavity, the opening of wounds, hematoma, displacement of implants in the interior of the sinus, fenestrations, oroantral fistula, epistaxis, perforation of the Schneiderian membrane, bone sequestra and acute sinusitis.<sup>1,3-5,8,9</sup> The latter is considered the main drawback of this procedure, being most frequent in patients who undergo a sinus augmentation with lateral access, leading to the contamination of the graft and the loss of the implants.<sup>4,8</sup>

The following case describes the treatment of this disorder with abundant sinus rinsing with salt water and combined treatment of antibiotics and mucolytics without the need for removal of the implant or bone graft.

### CASE.

A male patient, aged 40, with no significant medical history visited the clinic to restore the tooth 2.6 using an implant. After observing the CT scan and confirming that there was not enough height, a decision was made for sinus augmentation surgery with lateral access (See figure 1a, 1b).

The surgical treatment started with anaesthetic infiltration using 1.8ml of Lidocaine with epinephrine 1: 80,000, with a crestal incision in the edentulous area slightly towards the palatine, from the area of the first upper premolar, together with two releasing incisions in the vestibular mucosa, at the level of the mesial and distal ends of that incision, oblique, to obtain a flap wider at its base, which gives a sufficiently broad area.

The osteotomy of the access window to the maxillary sinus was carried out in the anterior wall (Caldwell-Luc style), using a reamer instrument (KIT SLA Neobiotech) at high speed and with abundant sterile saline irrigation. Once the Schneiderian membrane has been completely lifted, with its entirety being visible during the whole elevation process, a Bio-Gide collagen membrane (Geistlich Pharma AG, Wolhusen, Switzerland, of 25x25mm.) was then placed, which serves as a roof and a barrier between the sinus membrane and the Bio-Oss Xenograft (Geistlich Pharma AG, Wolhusen, Switzerland; granulometry 1mm-2mm), mixed with autologous bone previously obtained

from the tuberosity.

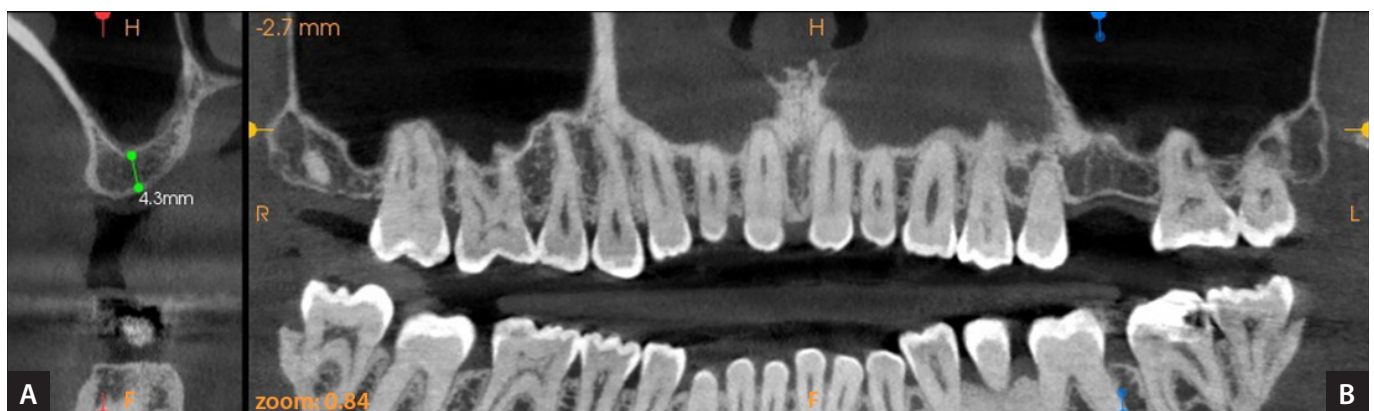
A Radhex (Spain) implant of 5x10mm was then placed with a torque of 40Ncm. The flap was repositioned and sutured using simple and mattress stitches. For this procedure, a nylon monofilament suture of 6.0 was used, with no tension, achieving a careful sealing of the soft tissue and a hermetic seal.

Once the surgical procedure was over, the patient was given treatment with antibiotics – clindamycin 300mg orally every 8 hours – and non-steroid anti-inflammatories – ketoprofen 100mg orally every 8 hours – prescribed for 5 days postoperatively, together with a chlorhexidine mouthwash. The patient was informed of the postoperative measures which are common to all oral surgery (apply ice, soft diet, no smoking, and light bed rest). The patient was advised to avoid any activities which might involve high pressure for the first few days after surgery (scuba diving, flights in unpressurised cabins, sneezing).

After three weeks, the patient visited the clinic once again, complaining of pressure when he tilted his head forward, posterior nasal discharge (drops of mucus in the throat with bone granules), swelling and pain to touch; all of which are clear symptoms of acute sinusitis which was later confirmed with a CT scan (See figures 2a, 2b, 2c).

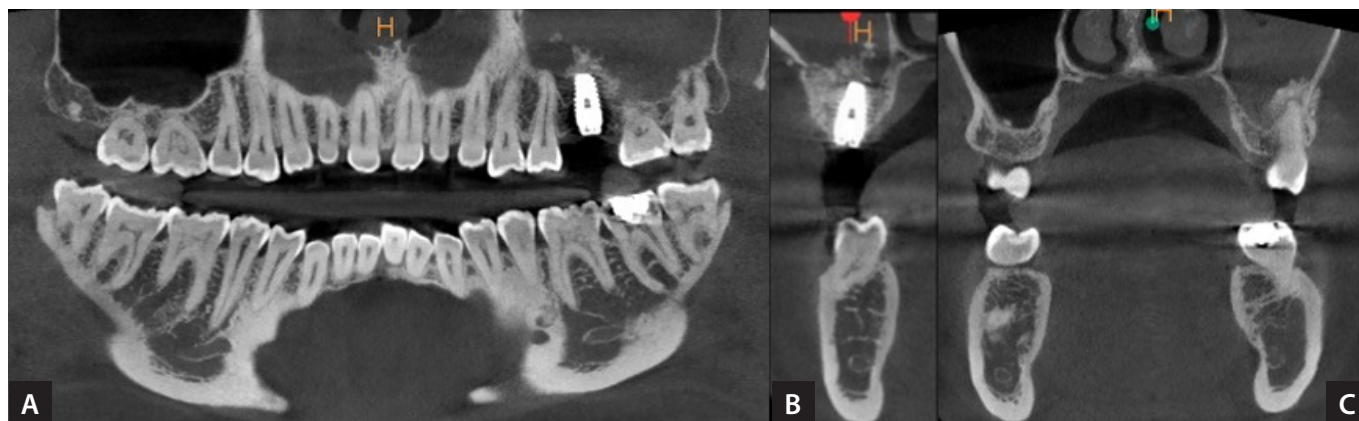Questioning the patient in search of possible causes, the patient commented that a few days after the operation, he sneezed forcefully after which, the symptoms started. Therefore, this led to a suspected perforation of the Schneiderian membrane. As a result, the decision was made to medicate the patient with amoxicillin and clavulanic acid 875/125mg, 3 times a day for 10 days, cefuroxime

**Figure 1.** Preoperative images that show the available height of 4.3mm.



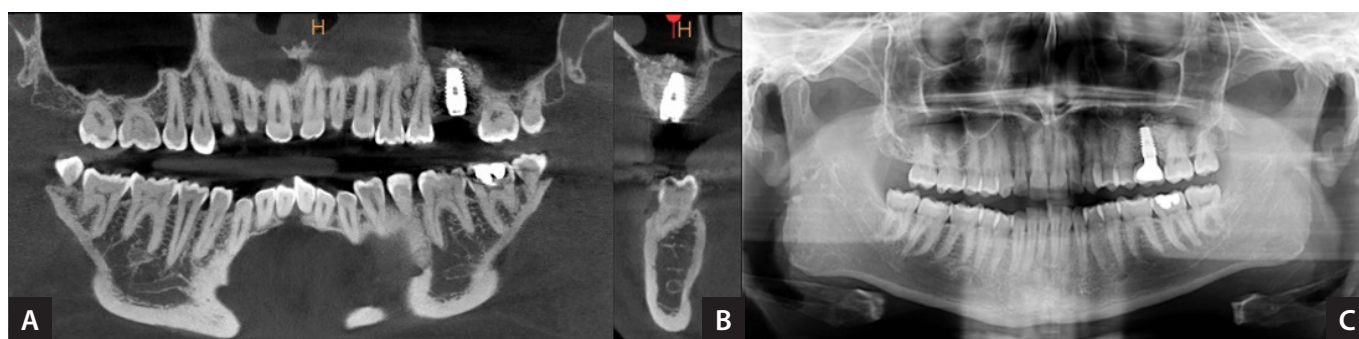
A: Axial section. B: Panoramic view.

**Figure 2.** Images which show the occupation of the left maxillary sinus.



A: Panoramic view. B: Transverse section. C. Frontal view.

**Figure 3.** Images which show the remission of the sinusitis.



A: Panoramic view. B: Cross section. C: Panoramic view after a year with the implant loaded.

axetil 500mg every 12 hours for 10 days, ibuprofen 600mg every 8 hours for 4 days, acetylcysteine 600mg once a day for 10 days and sinus rinses by nasal administration with physiological serum for 20 days. At the conclusion of this period, the patient returned for a check-up, with the total remission of the symptoms. As a result, six months were allowed to elapse before carrying out a new CT scan and to check that the sinus was clean so the implant could be loaded (See figures 3a and 3b). After a year, the patient underwent a further check-up at the clinic, having a panoramic x-ray which confirmed that the implant is still in place and there are no signs of sinusitis. Figure 3C.

## DISCUSSION.

At present, it is accepted that the success rate in placing implants with augmentation of the maxillary sinus is quite high, corroborated by Wallace *et al.*, Hurzeler *et al.* and Del Fabbro *et al.* in their studies with a 91.8%, 90.3% and 91.49% success rate respectively.<sup>1</sup>

On reviewing the literature, no significant statistical dif-

ference has been found that affects the survival of the implants with simultaneous sinus augmentation; with regards to the diameter or position of these implants, the technique used, the gender or the perforation of the membrane are relevant factors, as was observed by Ivanoff *et al.*, Zitzmann *et al.*, Smith *et al.* and Young-Kyun Kim respectively.<sup>1</sup> Jung *et al.* retrospectively reviewed nine cases in which 23 of the implants placed penetrated more than 4mm into the maxillary sinus (5mm on average, with a range of 4-7mm) without carrying out any membrane elevation procedure and in none of the cases was sinusitis observed.<sup>3</sup>

It was also observed that the success rate of implants placed with sinus augmentation significantly decreases when maxillary sinusitis develops, reaching success rates between 20% and 40% in those cases in which it was present versus 90% in those in which it was not present.<sup>1,4</sup> Khanberg *et al.*, reported signs of infection in 8 out of 36 patients, which represents a higher prevalence.<sup>2</sup>

Although many theories have been put forward with regards to the etiology of maxillary sinusitis, such as

genetic predisposition, structural abnormalities, allergies, infections by anaerobic bacteria (*Staphylococcus aureus*, *Peptostreptococcus spp*) or by fungi, the majority of cases are currently considered idiopathic.<sup>3,10</sup> In this case, the appearance of sinusitis seems to be related to the perforation of the Schneiderian membrane and the dispersion of graft material which could have caused the obstruction of the ostium as well as a disorder in the ciliary function of the sinus mucosa, coinciding with Cho-Lee *et al.*, who reported that the perforation of the membrane brought with it an increase in sinusitis, peri-implantitis and the subsequent loss of the implant.<sup>4</sup>

The treatment of sinusitis can often be very complex and traumatic for the patient. It normally involves antibiotic treatment combined with surgical or endoscopic procedures aimed at eradicating the disorder, which can involve the removal of the implants and bone grafts separately or at the same time. In complex cases, such as prolonged infections, even the most careful surgical procedure cannot guarantee the complete elimination of the disease.<sup>2,3,8,11,14</sup> Hence the peculiarity of this case, as no mention was found in the literature about a case of sinusitis after open sinus augmentation in which the disorder was resolved with abundant sinus rinses with salt water and a combined therapy of antibiotics and mucolytics, without the need for the complete removal of the implant

or the bone graft. In this case, amoxicillin + clavulanic acid 875mg was chosen as it is a broad spectrum antibiotic and because this combination allows for the treatment of bacterial infections resistant to amoxicillin alone. Additionally, clavulanic acid is a powerful  $\beta$ -Lactamase inhibitor to combat infections generated by *Staphylococcus aureus* which, as stated above, is frequently associated with acute maxillary sinusitis. In addition, cefuroxime-axetil 500mg was also used, as it offers action against aerobic Gram negative and positive bacteria, such as *Staphylococcus aureus* and both Gram positive and Gram negative bacteria, such as *Peptostreptococcus*. It is also suitable for its action against infections of the upper respiratory tract, such as ear, nose and throat infections, otitis media, tonsillitis, pharyngitis and, as in our case, sinusitis.

## CONCLUSION.

Sinus floor augmentation is considered a safe and reliable procedure, however, despite this, special care should be taken in cases of sinusitis. Dealing with this disorder should be carried out immediately with the objective of reducing the risk of possible complications. Despite the disorder in this case being eradicated with a different approach combining antibiotics, mucolytics and sinus rinses, it is concluded that more studies are necessary before it is established as a definitive treatment procedure.

## REFERENCES.

1. Kim YK, Ahn KJ, Yun PY. A retrospective study on the prognosis of single implant placed at the sinus bone graft site. Oral Surg Oral Med Oral Pathol Oral Radiol. 2014;118(2):181–6.
2. Chirilă L, Rotaru C, Filipov I, Săndulescu M. Management of acute maxillary sinusitis after sinus bone grafting procedures with simultaneous dental implants placement - a retrospective study. BMC Infect Dis. 2016;16(Suppl 1):94.
3. Kayabasoglu G, Nacar A, Altundag A, Cayonu M, Muhtarogullari M, Cingi C. A retrospective analysis of the relationship between rhinosinusitis and sinus lift dental implantation. Head Face Med. 2014;10:53.
4. Kim YK, Hwang JY, Yun PY. Relationship between prognosis of dental implants and maxillary sinusitis associated with the sinus elevation procedure. Int J Oral Maxillofac Implants. 2013;28(1):178–83.
5. Park JS, Kim BC, Choi B, Lee J. Facial skin fistula as a postoperative complication related to maxillary sinus grafting: A case report. Quintessence Int. 2015;46(2):145–8.
6. Nooh N. Effect of schneiderian membrane perforation on posterior maxillary implant survival. J Int Oral Health. 2013;5(3):28–34.
7. Nam KY, Kim JB. Treatment of dental implant-related maxillary sinusitis with functional endoscopic sinus surgery in combination with an intra-oral approach. J Korean Assoc Oral Maxillofac Surg. 2014;40(2):87–90.
8. Alkan A, Celebi N, Baş B. Acute maxillary sinusitis associated with internal sinus lifting: report of a case. Eur J Dent. 2008;2(1):69–72.
9. İşler SC, Cansiz E, Ulsan M, Güldiken Y. One Stage Operation for the Treatment of a Complicated Maxillary Sinusitis Due to Complication of Sinus Lifting Procedure: Case Report. Türkiye Klinikleri J Dental Sci. 2015;21(3):240–6.
10. Akhlaghi F, Esmacelnejad M, Safai P. Etiologies and Treatments of Odontogenic Maxillary Sinusitis: A Systematic Review. Iran Red Crescent Med J. 2015;17(12):e25536.
11. Matsumoto Y, Okuno T, Hasegawa Y, Kuwauchi M. Dual antrostomy optical window for visualising sinus cavity during implant restoration. BMJ Case Rep. 2012;2012:pii: bcr0220125869.
12. Felisati G, Chiapasco M, Lozza P, Saibene AM, Pipolo C, Zaniboni M, Biglioli F, Borloni R. Sinonasal complications resulting from dental treatment: outcome-oriented proposal of classification and surgical protocol. Am J Rhinol Allergy. 2013;27(4):e101–6.
13. Di Pasquale D, Saibene AM, Bebi V, Felisati G. Calcifications afloat: bad omens in maxillary sinus augmentation. BMJ Case Rep. 2013;2013:pii: bcr2013201581.
14. Young-Kyun K, Pil-Young Y, Ji-Su O, Su-Gwan K. Prognosis of closure of large sinus membrane perforations using pedicled buccal fat pads and a resorbable collagen membrane: case series study. J Korean Assoc Oral Maxillofac Surg. 2014;40(4):188–94.