

Combined periodontal regeneration of molar severely compromised by furcation, intrabony defects and attachment loss to the apex: A Case Report.

Regeneración periodontal combinada de molar gravemente comprometido por furcación, defectos intraóseos y pérdida de inserción en el ápice: Reporte de un caso.

Héctor Oñate.¹

Jaime Segovia-Chamorro.^{2,3}

Affiliations:

¹School of Health Sciences, Universidad Viña del Mar, Viña del Mar, Chile

²Department of Conservative Dentistry, Faculty of Dentistry, Universidad Andres Bello, Viña del Mar, Chile.

³Department of Periodontics, Faculty of Dentistry, Universidad de Valparaíso, Valparaíso, Chile.

Corresponding author: Héctor Oñate. School of Health Sciences, Universidad Viña del Mar, Viña del Mar, Chile. Agua Santa 7055, sector Rodelillo, Viña del Mar, Chile. **Phone:** (56-9) 6214 4449. **Email:** hector.onate.n@gmail.com

Receipt : 08/18/2020 **Revised:** 02/06/2021
Acceptance: 04/28/2021

Cite as: Oñate H & Segovia-Chamorro J.

Combined periodontal regeneration of molar severely compromised by furcation, intrabony defects and attachment loss to the apex: A Case Report.

J Oral Res 2021; 10(1):1-7.

Doi:10.17126/joralres.2021.024

Abstract: Introduction: Clinicians tend to encounter unfavorable situations in the treatment of teeth with severe attachment loss. Periodontal regeneration has been a successful therapeutic approach in treatments that require a long-term prognosis improvement. This case shows the benefits of combined regenerative periodontal therapy in a patient with a molar severely compromised by furcation, intrabony defects and attachment loss to the apex. **Case Report:** The clinical case included an endo-periodontal, class III furcation and intrabony defects in a generalized periodontitis, Stage III Grade C patient. After non-surgical periodontal treatment and re-evaluation, a full-thickness flap and surgical debridement were performed. Dental root surface was treated with EDTA and enamel matrix derivatives and the defects were filled with allograft and platelet-rich fibrin, additionally a collagen membrane was applied over the graft. After a 12-month follow-up there was a resolution of the intrabony defects and periodontal regeneration. Clinical and radiographic evaluation also showed the partial resolution of the class III furcation defect. **Conclusion:** Combined periodontal regeneration can be a therapeutic approach to improve the prognosis and prevent the extraction of molars severely compromised by furcation, intrabony defects and attachment loss to the apex.

Keywords: Guided tissue regeneration, periodontal; furcation defect; periodontitis; periodontal attachment loss; platelet-rich fibrin; case report.

Resumen: Introducción: Los clínicos tienden a encontrar situaciones desfavorables en el tratamiento de dientes por pérdida de inserción severa. La regeneración periodontal ha sido un enfoque terapéutico exitoso en tratamientos que requieren una mejora del pronóstico a largo plazo. Este caso demuestra los beneficios de la terapia periodontal regenerativa combinada en un paciente con un molar gravemente comprometido por furcación, defectos intraóseos y por pérdida de inserción hasta el ápice. **Reporte de caso:** El caso clínico incluyó un defecto endoperiodontal, furcación clase III y defectos intraóseos en una Periodontitis estadio III generalizada grado C. Tras el tratamiento periodontal no

quirúrgico y la reevaluación, se realizó un colgajo de espesor total y un desbridamiento quirúrgico. La superficie de la raíz dental se trató con EDTA y derivados de la matriz de esmalte y los defectos se rellenaron con aloinjerto y fibrina rica en plaquetas, adicionalmente se aplicó una membrana de colágeno sobre el injerto. Después de un seguimiento de 12 meses hubo resolución de los defectos intraóseos y regeneración periodontal. La evaluación clínica y radiográfica

también mostró la resolución parcial del defecto de furcación de clase III. **Conclusión:** La regeneración periodontal combinada puede ser un abordaje terapéutico para mejorar el pronóstico y prevenir la extracción de molares severamente comprometidos por furcación, por defectos y hasta el ápice.

Palabra Clave: Regeneración tisular guiada periodontal; defectos de furcación; periodontitis; pérdida de la inserción periodontal; fibrina rica en plaquetas; reporte de caso.

INTRODUCTION.

Studies have shown that the use of Enamel Matrix Derivatives (EMD) has biological potential for periodontal repair and/or regeneration, improving clinical results in furcation and intrabony defects.¹

Clinicians often combine different techniques in regeneration, especially when treating non-containing defects.² The combination of EMD and different types of grafts have been extensively evaluated in preclinical and clinical studies.³ However, despite the encouraging results in intrabony defects regeneration, there is lack of evidence related to guided tissue regeneration with EMD in class III furcation defects. This is due to the clinician's difficulty in creating ideal conditions for the regeneration of class III furcation defects, such as, the provision of space, wound stability and local factors. Another issue is the absence of bony walls that generate the necessary vascular and cellular contribution in this type of defects.⁴ The objective of this case report is to present a clinical case of a periodontal regeneration using a combined approach to treat a molar severely compromised by furcation, intrabony defects and attachment loss to the apex.

CASE REPORT.

Clinical presentation

The patient had not been to a dental appointment for eight years prior to the dental treatment presented here. The patient was a clinically healthy, non-smoking 32-year-old female, who presented with eccentric bruxism, disc displacement with a reduction in the right TMJ, and multiple non-carious cervical lesions; O'Leary plaque score index of 64% and bleeding on probing of 48% were recorded (Table 1).

Orthopantomography (Pax-i SC, Vatech, Hwaseong-si, Gyeonggi-do, South Korea) showed severe bone

destruction in vertical and horizontal patterns along the molar region, furcation defects in upper molars and tooth 3.6 (Figure 1). Furthermore, a microbiological examination was performed by conventional polymerase chain reaction (PCR) (GoTaq, WI, USA) for keystone pathogens, testing positive for *Porphyromonas gingivalis* and *Aggregatibacter actinomycetemcomitans*.

A periodontal chart was recorded obtaining an average clinical attachment loss (CAL) of 6.37 mm and an average periodontal probing depth of 6.95 mm, with a diagnosis of generalized periodontitis stage III grade C.⁵ Periodontal debridement therapy was performed in combination with adjunctive systemic antibiotics (amoxicillin 500 mg every eight hours for 14 days plus metronidazole 250 mg every eight hours for 14 days).⁶

Finally, the patient was referred to a specialist in temporomandibular disorders. There was a complete resolution of the periodontal pockets, except in tooth 3.6, at two months follow-up (Table 1).

Therefore, a combined periodontal regeneration therapy in tooth 3.6 was performed. The prognosis of the aforementioned tooth was unfavorable because of an intrabony defect, a class III furcation defect, and a class 3 endo-periodontal lesion in a periodontitis patient and in teeth 4.6 and 4.7, which presented less severe mesial intrabony defects.

Case management

After local anesthesia was achieved, an intrasulcular incision was made with a 15c blade (Hu-Friedy, Chicago, IL, USA). Then, a full-thickness flap without vertical releasing incisions was raised extending from distal of tooth 3.7 to distal of tooth 3.3. Bone defect and root debridement was performed with gracey curettes (Hu-Friedy, Chicago, IL, USA) and copious irrigation with saline solution.

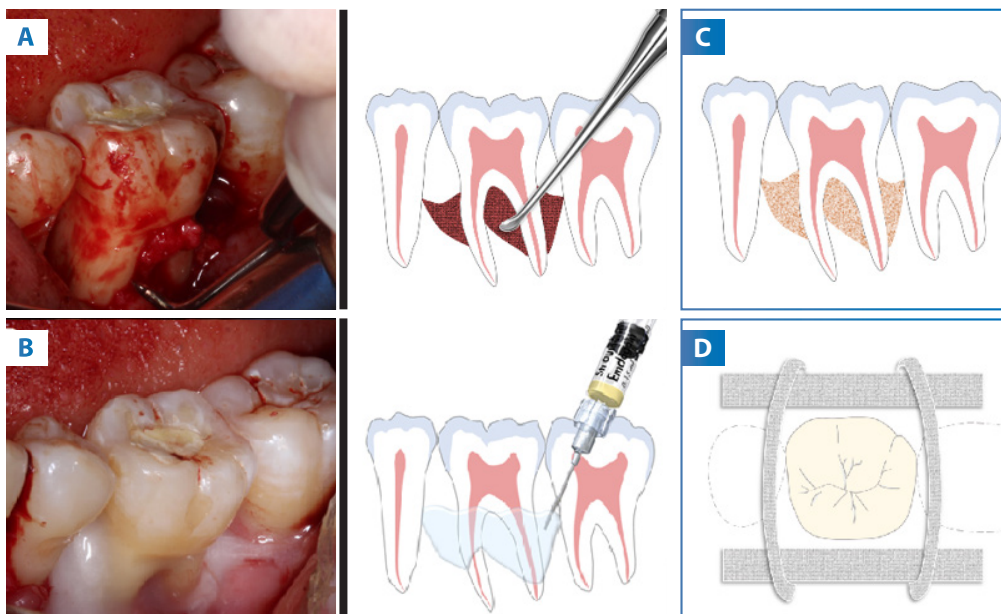
Tooth 3.6 (with endodontic treatment completed one week *prior* to the corrective phase) exhibited an extensive apical lesion associated with marked loss of inter-radicular bone. Root surface conditioning was done using 24% ethylenediaminetetraacetic acid (EDTA) (PrefGel, Institute Straumann, Basel, Switzerland) for two minutes and saline solution irrigation. After the surface conditioning,

EMD (Emdogain, Institute Straumann, Basel, Switzerland) was applied for another five minutes without rinsing the area. Simultaneously, during the surgery, blood was taken from the patient to obtain platelet-rich fibrin (PRF) by centrifuging the patient's blood at 2700 rpm for 12 minutes (Low-speed centrifuge LC-04B Plus, Globalroll, Zhejiang, China).

Figure 1. Pretreatment radiographs. Severe bone loss with a vertical pattern at first upper and lower molars are suggested. Furcation lesions are evident in most of the first molars, with apex involvement in 36.

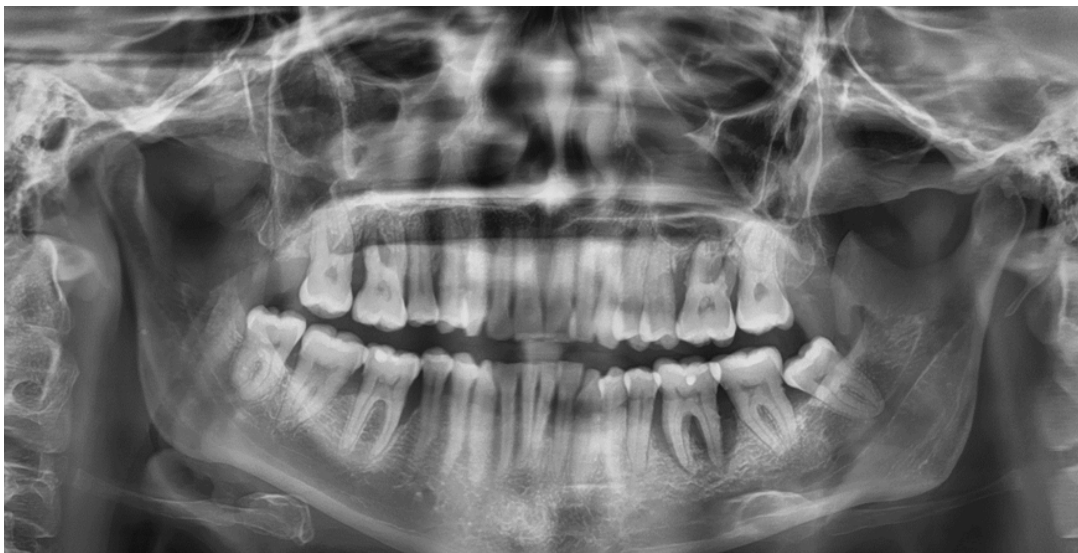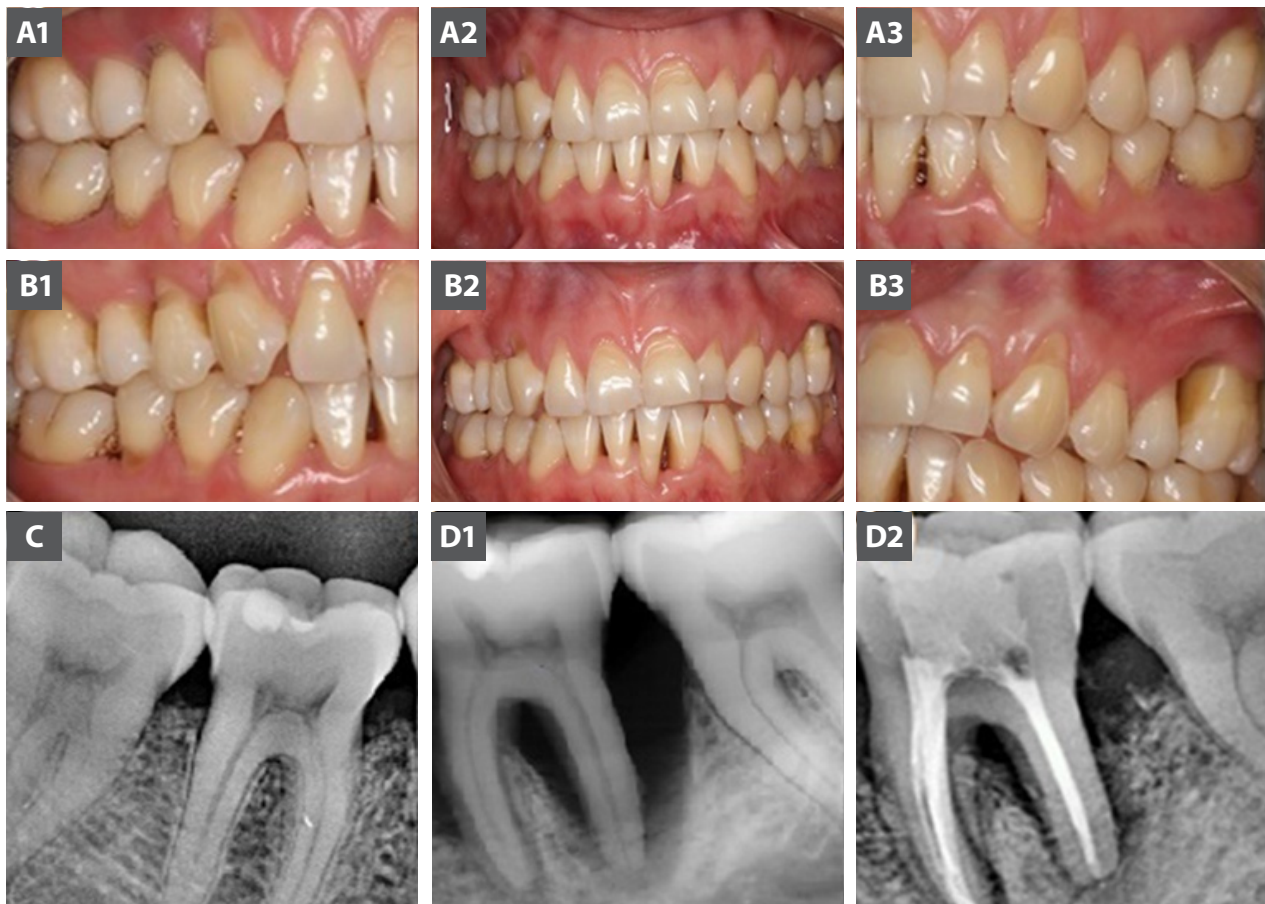


Figure 2. Procedure intrasosseous defects of teeth 4.6 and 4.7.



A: Surgical debridement of the furcation and intrabony defect through a periodontal flap. **B:** Application of the Enamel Matrix Derivatives in the root surfaces. **C:** Bone graft scheme. **D:** Planning the position of collagen membranes to recover lost osseous walls.

Figure 3. Clinical outcomes.



A1, A2, A3: Initial clinical presentation showing gingival recessions, non-carious cervical lesions with few inflammation signs. **B1, B2, B3:** 12-month clinical presentation. **C:** 12-months periapical radiography of teeth 46, complete resolution of intrabony defect is noticeable. **D1:** Initial radiograph. **D2:** 12-months radiograph of teeth 46, showing resolution of intrabony defect passing to a horizontal defect. The reduction of the furcation lesion is evident, as well.

Table 1. Periodontal parameters before and after periodontal treatment.

Variables	Baseline	Reevaluation Phase	1 year control
Number of sites with Probing Depth \geq 5 mm	49/168	2/168	3/168
Number of sites with Probing Depth \geq 6 mm	34/168	0/168	0/168
Number of sites with Probing Depth \geq 7 mm	27/168	0/168	0/168
Number of sites with Clinical Attachment Level \geq 5 mm	50/168	30/168	31/168
Average Probing Depth	6.95 mm	3.52 mm	3.56 mm
Average Clinical Attachment Level	6.37 mm	5.02 mm	5.05 mm
% of sites with plaque accumulation	64	3	22
% of sites with bleeding on probing	48	1	34

Subsequently, the PRF was mixed with 0.5 ml allograft (MinerOss, Biohorizons, Birmingham, AL, USA) obtaining growth factors-enriched bone graft matrix.⁷ Bone graft was compacted in the intraosseous defects and the furcation lesion in tooth 3.6. A resorbable collagen membrane (Memlock, Birmingham, USA) was used in vestibular, lingual, and interproximal areas with free-tension closure by first intention achieved through a coronally positioned flap. The procedure was repeated for intraosseous defects of teeth 4.6 and 4.7 but without EMD since the defects were contained.⁴ (Figure 2)

Clinical outcomes

Redness, pain, and exudate were not observed at any time. After 12 months, there was a regeneration in teeth 4.7 and 4.6 observed clinically and through radiographs. Resolution of intrabony defect was observed in tooth 3.6. There was a partial regeneration of the class III furcation lesion, and grade I mobility remained stable over time (Figure 3).

DISCUSSION.

Intrabony and furcation defects are a challenge in periodontal treatment. Depending on the severity and location, the patient may struggle maintaining adequate hygiene in the area and hinder proper periodontal maintenance. Therefore, regenerative therapies have gained interest, since the possibility of modifying a predisposing cause, such as anatomical local factors, would improve the prognosis over time; thereby, guaranteeing long-term periodontal stability.⁴ Periodontal regeneration treatment, in comparison to implant therapy, has shown similar results in dental implant stability and quality of life. Additionally, there has been less economical cost in cases where the bone loss has reached the apex.⁸

A range of materials have been used to promote and stimulate periodontal regeneration; however, most of them have presented limited results. In recent times, EMD has been used for the treatment of a variety of periodontal defects, both in animal and clinical studies, to generate a predictable therapeutic approach in clinical situations. Biological plausibility lies in the stimulation and modulation of repair, favoring the resolution of inflammation, cell differentiation, and neovascular formation.^{1,9} The results of this case report are encouraging; there was gaining of CAL, resulting in a significant improvement in the non-contained intrabony defects. The class III furcation defects presented similar results to the literature.^{10,11} However, existing publications are scarce to date, there are no clinical studies

with a high level of evidence to compare the use of EMD in mandibular furcation type III lesions in the long term. A series of cases evaluated the class III treatment of furcation defects with the use of EMD alone or in combination with a resorbable membrane.

No treatments resulted in a complete repair of the defect, concluding that this type of procedure is not predictable in class III furcation defects of mandibular molars.¹² Recently, a case series report has shown that regenerative therapy in teeth with combined intrabony and furcation lesions in compliant subjects can have clinical improvements and tooth retention when the teeth were not mobile.¹³ These findings support our therapeutic approach, encouraging to incorporate minimally invasive surgical techniques, such as papilla preservation flaps.

Although, there is lack of evidence regarding the use of PRF in furcations and intrabony defects; some results found in class II furcations showed better outcomes using PRF in comparison to open flap debridement¹⁴⁻¹⁶ and bioactive glass¹⁷ in terms of defect filling. The studies of PRF in guided tissue regeneration of furcation lesions are scarce,¹⁵ however, there are promising comparable results in recent investigations.¹⁸ The use of PRF in intrabony defects has shown good results compared to open flap debridement,^{15,16} having better soft tissue healing¹⁹ and in comparative clinical outcomes with guided tissue regeneration.¹⁵ Additionally, the use of PRF as an adhesive could improve the performance of bioactive glass in the filling of intrabony defects.²⁰

Despite the results being similar to the literature, from a clinical and radiographic point of view, the changes in clinical parameters are evident, considerably improving the prognosis of tooth 3.6, where bony defects were modified from vertical to horizontal and there was a partial resolution of the furcation defect, leading the preservation of tooth instead of extraction and implant therapy.

CONCLUSION.

It was observed through this study that in the case of molars severely compromised by furcation, intrabony defects, and attachment loss to the apex; a combined periodontal regeneration treatment can be a plausible alternative to avoid extraction in compliant subjects.

Patient Perspective

In my first dental consultation, I went for a tooth inflammation, not knowing that it was something bigger than my teeth. Knowing the diagnosis given by the doctor, a comprehensive periodontal treatment began,

focused mainly on the tooth where I had bone loss. I also had a root canal in the same tooth.

After a long work by the doctor and specialists, a surgical procedure was performed focused on the two lower teeth. After that, the X-rays showed bone growth and I felt more firmness in my molars. The truth is that I am very happy and grateful to the doctor for all his help, concern, as well as the professional and good person he is. The treatment was a complete success. Thank you very much.

Conflict of interests: The authors declare that they have no conflict of interest.

Ethics approval: Patient provided informed consent.

Funding: Self-financed.

Authors' contributions: All authors contributed to the manuscript equally.

Acknowledgements: The authors would like to thank Fernanda McLintock and Manuel Gajardo for their contribution to this manuscript.

REFERENCES.

1. Miron RJ, Sculean A, Cochran DL, Froum S, Zucchelli G, Nemcovsky C, Donos N, Lyngstadaas SP, Deschner J, Dard M, Stavropoulos A, Zhang Y, Trombelli L, Kasaj A, Shirakata Y, Cortellini P, Tonetti M, Rasperini G, Jepsen S, Bosshardt DD. Twenty years of enamel matrix derivative: the past, the present and the future. *J Clin Periodontol.* 2016;43(8):668-83.
2. Sculean A, Alessandri R, Miron R, Salvi GE, Bosshardt DD. Enamel Matrix Proteins and Periodontal Wound Healing and Regeneration. *Clin Adv Periodont.* 2011;1(2):101-17.
3. Matarasso M, Iorio-Siciliano V, Blasi A, Ramaglia L, Salvi GE, Sculean A. Enamel matrix derivative and bone grafts for periodontal regeneration of intrabony defects. A systematic review and meta-analysis. *Clin Oral Investig.* 2015;19(7):1581-93.
4. Sanz M, Jepsen K, Eickholz P, Jepsen S. Clinical concepts for regenerative therapy in furcations. *Periodontol 2000.* 2015;68(1):308-32.
5. Tonetti MS, Greenwell H, Kornman KS. Staging and grading of periodontitis: Framework and proposal of a new classification and case definition. *J Clin Periodontol.* 2018;45 Suppl 20:S149-S61.
6. Feres M, Figueiredo LC, Soares GM, Favari M. Systemic antibiotics in the treatment of periodontitis. *Periodontol 2000.* 2015;67(1):131-86.
7. Choukroun J, Adda F, Schoeffler C, Vervelle A. PRF: An opportunity in perio-implantology. *Implantodontie.* 2000;42:55-62.
8. Cortellini P, Stalpers G, Mollo A, Tonetti MS. Periodontal regeneration versus extraction and dental implant or prosthetic replacement of teeth severely compromised by attachment loss to the apex: A randomized controlled clinical trial reporting 10-year outcomes, survival analysis and mean cumulative cost of recurrence. *J Clinical Periodontol.* 2020;47:768-76.
9. Shirakata Y, Miron RJ, Nakamura T, Sena K, Shinohara Y, Horai N, Bosshardt DD, Noguchi K, Sculean A. Effects of EMD liquid (Osteogain) on periodontal healing in class III furcation defects in monkeys. *J Clin Periodontol.* 2017;44(3):298-307.
10. Palioto DB, de O Macedo G, Queiroz AC, Taba M Jr, Souza SL, Grisi MF, Novaes AB Jr. Enamel matrix derivative and transforming growth factor-beta1 in Class III furcation defects. A histomorphometric study in dogs. *J Int Acad Periodontol.* 2012;14(3):69-75.
11. Hovey LR, Jones AA, McGuire M, Mellonig JT, Schoolfield J, Cochran DL. Application of Periodontal Tissue Engineering Using Enamel Matrix Derivative and a Human Fibroblast-Derived Dermal Substitute to Stimulate Periodontal Wound Healing in Class III Furcation Defects. 2006;77(5):790-9.
12. Donos N, Glavind L, Karring T, Sculean A. Clinical evaluation of an enamel matrix derivative and a bioresorbable membrane in the treatment of degree III mandibular furcation involvement: a series of nine patients. *Int J Periodontics Restorative Dent.* 2004;24(4):362-9.
13. Cortellini P, Cortellini S, Tonetti MS. Papilla preservation flaps for periodontal regeneration of molars severely compromised by combined furcation and intrabony defects: Retrospective analysis of a registry-based cohort. *J Periodont.* 2020;91(2):165-73.
14. Panda S, Karanxha L, Goker F, Satpathy A, Taschieri S, Francetti L, et al. Autologous Platelet Concentrates in Treatment of Furcation Defects-A Systematic Review and Meta-Analysis. *Int J Mol Sci.* 2019;20(6).
15. Miron RJ, Zucchelli G, Pikos MA, Salama M, Lee S, Guillemette V, Fujioka-Kobayashi M, Bishara M, Zhang Y, Wang HL, Chandad F, Nacopoulos C, Simonpieri A, Aalam AA, Felice P, Sammartino G, Ghanaati S, Hernandez MA, Choukroun J. Use of platelet-rich fibrin in regenerative dentistry: a systematic review. *Clin Oral Investig.* 2017;21(6):1913-27.
16. Castro AB, Meschi N, Temmerman A, Pinto N, Lambrechts P, Teughels W, Quirynen M. Regenerative potential of leucocyte- and platelet-rich fibrin. Part A: intra-bony defects, furcation defects and periodontal plastic surgery. A systematic review and meta-analysis. *J Clin Periodontol.* 2017;44(1):67-82.
17. Basireddy A, Prathypaty SK, Yendluri DB, Potharaju SP. Demineralized freeze-dried bone allograft with or without platelet-rich fibrin in the treatment of mandibular Degree II furcation defects: A clinical and cone beam computed tomography study. *J Indian Soc Periodontol.* 2019;23(3):242-8.
18. Asimuddin S, Koduganti RR, Panthula VNR, Jammula SP, Dasari R, Gireddy H. Effect of Autologous Platelet Rich Fibrin in Human Mandibular Molar Grade II Furcation Defects- A Randomized Clinical Trial. *J Clin Diagn Res.* 2017;11(4):ZC73-7.
19. Patel GK, Gaekwad SS, Gujjari SK, S C VK. Platelet-Rich Fibrin in Regeneration of Intrabony Defects: A Randomized Controlled Trial. *J Periodontol.* 2017;88(11):1192-9.
20. Bodhare GH, Kolte AP, Kolte RA, Shirke PY. Clinical and radiographic evaluation and comparison of bioactive bone alloplast morsels when used alone and in combination with platelet-rich fibrin in the treatment of periodontal intrabony defects-A randomized controlled trial. *J Periodontol.* 2019;90(6):584-94.