

Utility of the Backscattering Scanning Electron Microscopy in the Study of Peri-implantitis.

Utilidad de la microscopía electrónica de barrido de retrodispersión en el estudio de periimplantitis.

Ivan Valdivia-Gandur.^{1,2}
Wilson Astudillo-Rozas.²
María Manzanares-Céspedes.³

Affiliations:

¹Biomedical Department and Dentistry Department, Universidad de Antofagasta.

²Master of Biomedical Sciences, Health Science Faculty, Universidad de Antofagasta.

³Universitat de Barcelona, Human Anatomy and Embryology Unit, Muscular and Skeletal Pathology Research, Barcelona, Spain.

Corresponding author: Ivan Valdivia Gandur. Depto Biomédico, Universidad de Antofagasta, Avda Angamos # 601, Antofagasta, Chile. **E-mail:** ivan.valdivia.gandur@gmail.com

INTRODUCTION.

Bone tissue is frequently studied in decalcified samples, but this technique reduces the possibility of studying the relationship between bone tissue and high inorganic content biomaterials or dental implant surfaces. The backscattering scanning electron microscopy (BS-SEM) has been used to analyze bone tissue in undecalcified samples in resin (plastic inclusion) in order to describe the osseointegration of different biomaterials including dental implants.^{1,2}

In the study of peri-implantitis this technique has been less used, with preference given to histological analysis with different staining techniques in samples with or without plastic inclusion. The objective of this report is to show the utility of BS-SEM in the description of the bone morphology of samples with peri-implantitis.

Preliminary analysis

The explantation models and analysis of the samples was authorized by the Ethics Committee of the Universidad de la Frontera, Chile. The study considers the principles of Helsinki's statement. Four samples from patients with peri-implantitis without coexisting oral or systemic pathology were included in the study. The diagnosis of peri-implantitis was based on the consensus report of Workgroup 4 of the 2017 World Workshop on the Classification of Peri-implant Diseases and Conditions that considers the presence of bleeding and/or suppuration on gentle probing, probing depth ≥ 6 mm and bone level > 3 mm apical to the most coronal portion of the implant.³

The implants were extracted using a trephine considering at least 0.5 mm of space between the surface of the implant and the internal surface of the trephine. For the analysis of the samples, these were fixed in 4% formalin for 48 hours and then processed for plastic inclusion. Subsequently, the samples were cut with a diamond saw longitudinally to expose the area with the largest amount of remnant bone tissue for analysis by BS-SEM.

In a first stage, multiple microphotographs at 75x magnification were obtained from each sample, which were processed using photographic software and then used to assemble a larger microphotograph, thus displaying the general morphology of the relationship between the implant and remnant bone tissue. Subsequently, the obtention of microphotographs at 150-200x magnification of the bone tissue in contact with the implant

Cite as:

Valdivia-Gandur I, Astudillo-Rozas W & Manzanares-Céspedes M.

Utility of the Backscattering Scanning Electron Microscopy in the Study of Peri-implantitis.

J Oral Res 2020; S1(1):10-12

Doi:[10.17126/joralres.2020.026](https://doi.org/10.17126/joralres.2020.026)

was performed, which were analyzed considering the following parameters: areas with lamellar, fibroreticular and chondroid bone tissue; evidence of osteoclastic resorption lacunae; areas with increased and irregular osteocyte spaces.

Main findings and their utility in the study of peri-implantitis.

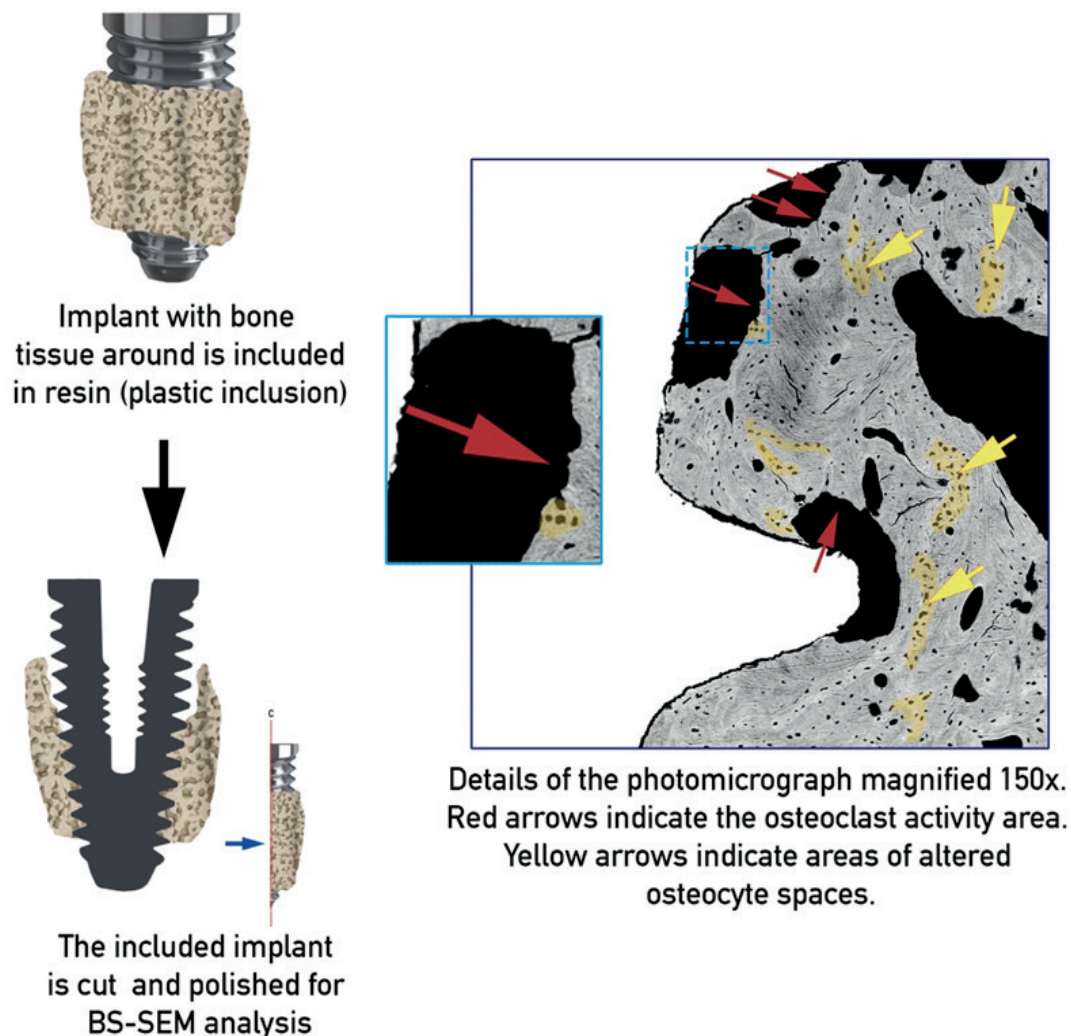
The BS-SEM analysis showed in all the samples a remnant bone tissue mainly formed by lamellar bone tissue, osteonal formation and wide vascular spaces, with little presence of fibroreticular and chondroid bone tissue, which is compatible with mature bone tissue. Although this aspect shows a well-organized bone around the implants, this only confirms that the

implants were correctly integrated after their initial insertion. The BS-SEM could evidence the osteoclastic resorption lacunae. Additionally, several sites with altered osteocyte spaces were observed, which could be associated to the action of the inflammatory process and the consequences of the increased loads on the remnant bone tissue (Figure 1).

In this regard, there is evidence in the literature that shows a relationship between the presence of pro-inflammatory molecules, the increase in the size of osteocyte spaces and increased osteoclastic activity.^{4,5}

Analysis of this information associated with other study methods can provide relevant information regarding the progress of peri-implantitis and treatment options.

Figure 1. Analysis by BS-SEM of a sample explanted due to peri-implantitis. BS-SEM show the bone tissue organization considering lamellar, fibroreticular and chondroid tissues. Additionally, BS-SEM show objectively the areas with osteoclast activity (resorption lacunae) and the altered form of osteocyte spaces.



Limitations of analysis by BS-SEM.

One of the limitations of the BS-SEM analysis is that it does not show cellular elements. However, this study can be complemented with the use of staining techniques for samples embedded in plastic. Still, the characteristics of bone morphology evidenced by the tissue organization, medullar and vascular spaces, the presence of osteoclastic resorption lacunae and the morphology of osteocyte spaces are objectively represented in the BS-SEM photomicrographs, so the cellular evidence only contributes to confirmation of the findings.

Finally, the BS-SEM is probably the best technique for bone tissue morphology analysis, but the number of samples obtained after cutting, grinding and polishing is limited. In this case, two or three segments of bone tissue in contact to the implant surface could be obtained.

Despite de abovementioned limitations, the study of peri-implantitis samples using BS-SEM can provide objective information about the quality of the remnant bone tissue and the severity of the damage generated by peri-implant pathology.

Acknowledgements: Grant REDI170658 from the Comisión Nacional de Investigación Científica y Tecnológica (CONICYT) from the Chilean Government.

REFERENCES.

1. Valdivia-Gandur I, Engelke W, Beltrán V, Borie E, Fuentes R, Manzanares-Céspedes MC. Novel use of cranial epidural space in rabbits as an animal model to investigate bone volume augmentation potential of different bone graft substitutes. *Head Face Med.* 2016;12(1):35.
2. Cirera A, Manzanares MC, Sevilla P, Ortiz-Hernandez M, Galindo-Moreno P, Gil J. Biofunctionalization with a TGFβ-1 Inhibitor Peptide in the Osseointegration of Synthetic Bone Grafts: An In Vivo Study in Beagle Dogs. *Materials.* 2019;12(19). pii: E3168.
3. Berglundh T, Armitage G, Araujo MG, Avila-Ortiz G, Blanco J, Camargo PM, Chen S, Cochran D, Derks J, Figuero E, Hämmeler CHF, Heitz-Mayfield LJA, Huynh-Ba G, Iacono V, Koo KT, Lambert F, McCauley L, Quirynen M, Renvert S, Salvi GE, Schwarz F, Tarnow D, Tomasi C, Wang HL, Zitzmann N. Peri-implant diseases and conditions: consensus report of workgroup 4 of the 2017 world workshop on the classification of periodontal and peri-implant diseases and conditions. *J Clin Periodontol.* 2018;45(20):286-91.
4. Yaghobee S, Khorsand A, Rasouli Ghohroudi A, Sanjari K, Kadkhodazadeh M. Assessment of interleukin-1beta and interleukin-6 in the crevicular fluid around healthy implants, implants with peri-implantitis, and healthy teeth: a cross-sectional study. *J Korean Assoc Oral Maxillofac Surg.* 2014;40(5):220-4.
5. Schaffler MB, Cheung WY, Majeska R, Kennedy O. Osteocytes: master orchestrators of bone. *Calcif Tissue Int.* 2014;94(1):5-24.