

Complete enucleation surgical treatment and histological analysis of a mucocele in lower lip in a child: Case Report.

Tratamiento quirúrgico de enucleación completa y análisis histológico de un mucocele en el labio inferior en un niño: Reporte de Caso.

Mariana Braga de Vasconcelos.¹
Daniela Novaes Soares.^{1,3}
Thais Campos Rodrigues Soares.¹
Gabriela Andrade Americano.^{1,3}
Roberto de Almeida Elias.²
Tatiana da Silva Fidalgo.^{1,3}

Affiliations: ¹Department of Pediatric Dentistry, Dental School, Salgado de Oliveira University, Niterói-RJ, Brazil. ²Department of Oral Surgery, Dental School, Salgado de Oliveira University, Niterói-RJ, Brazil. ³Department of Preventive and Community Dentistry, Dental School, State University of Rio de Janeiro, Rio de Janeiro-RJ, Brazil.

Corresponding author: Tatiana da Silva Fidalgo. Boulevard Vinte e Oito de Setembro, 157 Vila Isabel, Rio de Janeiro - RJ, 20551-030. Brazil. Phone:(55-21) 25690410. Email: tatianaksfidalgo@gmail.com

Receipt: 03/15/2019 **Revised:** 05/22/2019
Acceptance: 06/23/2019 **Online:** 12/30/2019

Cite as:

de Vasconcelos MB, Soares DN, Soares TCR, Americano GA, de Almeida Elias RE & da Silva Fidalgo T. Complete enucleation surgical treatment and histological analysis of a mucocele in lower lip in a child: Case Report.
J Oral Res 8(6):522-526.
Doi:10.17126/joralres.2019.072

Abstract: Objective: The aim of this case report is to describe the surgical removal of a mucocele and its histological analysis, in a child. Case Report: An 11-year-old female patient attended the Pediatric Dentistry clinic complaining of a lower lip lesion. During the anamnesis, the mother reported that the child had a habit of biting and sucking the spot frequently. Clinical examination showed the lesion was compatible with a mucocele. The proposed treatment was a complete enucleation of the lesion under local anesthesia. The incision and tissue divulsion were performed for maximum preservation of the mucosa, avoiding a possible recurrence. Total adjacent glands removal was also performed. The lesion was placed in 10% formaldehyde for histopathological analysis (H&E Staining), which showed dense connective tissue presenting chronic inflammatory infiltrate and extravasated mucin, presence of granulation tissue delimiting the area of extravasated mucin and presence of minor salivary glands. The patient was advised to quit the habit, and after seven days the sutures were removed. At the one-year follow-up there was no recurrence of the lesion. Conclusion: The proposed treatment proved to be effective without recurrence of the lesion.

Keywords: *Mucocele; pediatric dentistry; histological techniques; oral surgical procedures; lip; mucous membranes.*

Resumen: Objetivo: El objetivo de este reporte de caso es describir la extirpación quirúrgica de un mucocele y su análisis histológico en un niño. Informe del caso: una paciente de 11 años de edad asistió a la clínica de Odontopediatria quejándose de una lesión en el labio inferior. Durante la anamnesis, la madre informó que el niño tenía la costumbre de morder y chupar el lugar con frecuencia. En el examen clínico, la lesión fue compatible con un mucocele. El tratamiento propuesto fue una enucleación completa de la lesión bajo anestesia local. La incisión y la divulgación del tejido se realizaron para la máxima preservación de la mucosa, evitando una posible recurrencia. También se realizó la extracción total de las glándulas adyacentes. La lesión se colocó en formaldehído al 10% para el análisis histopatológico (tinción H&E), que mostró tejido conectivo denso que presenta infiltrado inflamatorio crónico y mucina extravasada, presencia de tejido de granulación que delimita el área de mucina extravasada y presencia de glándulas salivales menores. Se aconsejó al paciente que abandonara el hábito, y después de siete días se retiraron las suturas. En el seguimiento de un año no hubo recurrencia de la lesión. Conclusión: El tratamiento propuesto demostró ser efectivo sin recurrencia de la lesión.

Palabras Clave: *Mucocele; odontología pediátrica; técnicas histológicas; procedimientos quirúrgicos orales; labio; membrana mucosa.*

INTRODUCTION.

Mucoceles are known as retention cysts of the salivary glands. They are common lesions of the oral mucosa, especially in pediatric dentistry, and are characterized by a liquid retention phenomenon.^{1,2} These lesions are harmless cysts with saliva within, related to local trauma and obstruction of minor salivary glands.^{1,3,4}

The prevalence of oral mucoceles is 2.5 per 1000 people in the USA, it is thought to be the 17th most common lesion of the oral cavity,⁵ and is more prevalent in the second decade of life.⁶

Although clinical and experimental evidence has shown that traumatic injuries are the most likely cause of these lesions, in some cases it may be associated with congenital lesions such as Sjögren's Syndrome and cystic fibrosis. However, non-traumatic predisposing factors can also contribute to the development of these lesions.^{2,7-9}

Generally, they occur in the lower lip of children and adolescents, present clinically as a saliva-containing vesicle, have similar colouring to the adjacent area or are bluish mucosa, and their size may exceed 10mm in diameter.^{1,2,10} They may occur at different sites of the oral cavity, where the epithelium is less keratinized such as the anterior ventricle of the tongue, retrocommissural mucosa jugal mucosa, buccal floor and especially in the lower labial mucosa.

They are asymptomatic, and often there is spontaneous disruption. However, if there are several recurrences, surgical treatment is necessary to remove the adjacent salivary glands.¹

The literature shows several options for mucocele treatment and the choice should be based on the patient's age, location, size, depth of the lesion, and type of trauma involved. Among the proposed treatments, cryosurgery, laser, and surgical treatment by total excision of the lesion present a good prognosis.¹¹⁻¹⁷ The aim of this case report is to describe the surgical removal, in a child, of a mucocele and its histological analysis.

CASE REPORT

An 11-year-old female patient attended the Pediatric Dentistry clinic at Salgado de Oliveira University (Niterói) with her legal guardian, claiming that a "bubble" had appeared on her lower lip about two months previously.

During the anamnesis the mother reported that after her daughter had exfoliated the primary left inferior canine, a space remained, through which the child began to suck and bite the lower lip, and then the "bubble" appeared. The mother also reported that her daughter felt the bubble emptying and filling.

The clinical examination revealed the presence of an increased volume of soft consistency without altered coloration. The lesion did not present painful symptomatology, had a maximum of 2cm in diameter with a possible diagnosis of mucocele. (Figure 1A)

The treatment of choice was the total enucleation of the lesion and histopathological analysis. After one week, the biopsy was carried out. A proper asepsis was performed for the surgery. Then, a 2% benzocaine topical anesthetic was applied on the oral mucosa before the anesthesia of the mental nerve with 2% lidocaine. Also an infiltrative anesthesia in the labial mucosa around the lesion was performed, until reaching a slight ischemia of the tissue in order to have a cleaner surgery.

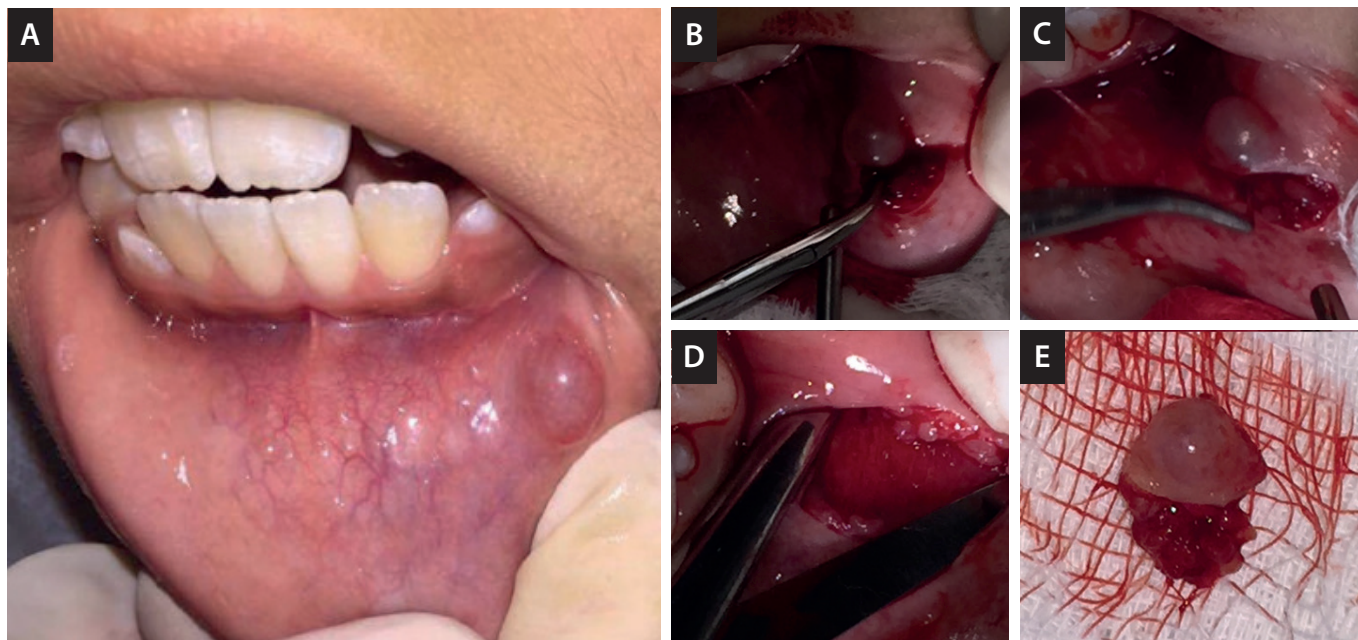
First, a rectilinear incision was made followed by aspiration. (Figure 1B) The divulsion was then started, performing the total complete enucleation of the lesion. (Figure 1C and Figure 1D)

Finally, suturing was performed and the excised tissue was placed in 10% formalin for histopathological analysis. (Figure 1E)

The patient was instructed to use ice packs on the external lip area, to restrict the diet to liquids and soft foods, to reduce bruising and swelling. After seven days, the patient returned to the Pediatric Dentistry clinic with good healing. (Figure 2A)

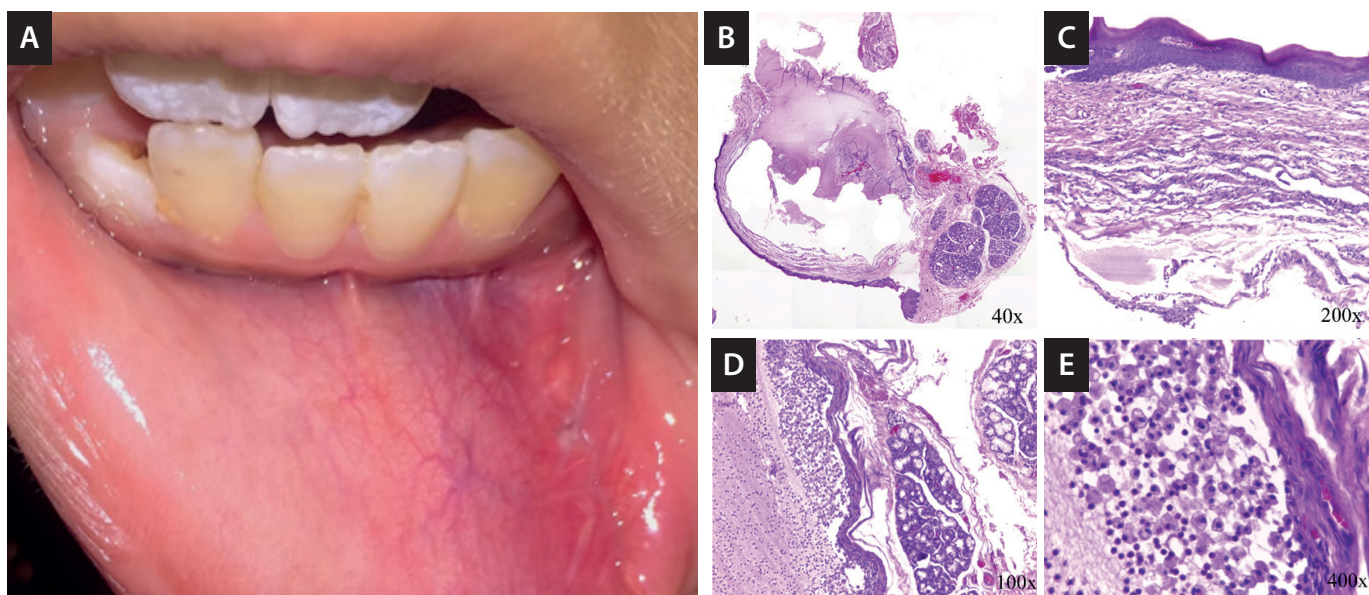
The mucocele was examined by hematoxylin and eosin (H&E) staining sections. (Figure 2B) The H&E staining confirmed the mucocele lesion diagnosis. The histological analysis revealed the following characteristics: parakeratinized stratified squamous epithelium (Figure 2C), minor salivary glands, and foamy macrophages and extravasated mucin (Figure 2D), granulation tissue delimiting the extravasated mucin area, lamina propria of dense connective tissue with chronic inflammatory infiltrate and extravasated mucin. (Figure 2E) At the one-year follow-up there was no recurrence of the lesion.

Figure 1: Clinical image of mucocele on the inferior lip and treatment.



A: Mucocele on the inferior lip. **B:** Incision of mucocele and divulsion by plane. **C:** The adjacent salivary glands were removed to avoid relapse. **D:** Lower lip without mucocele and after adjacent salivary gland removal. **E:** Mucocele for histological analysis.

Figure 2: Clinical image of surgical site seven days post mucocele removal.



A: Mucocele removal. **B:** H&E histological image of the lesion cavity (40x). **C:** Parakeratinized stratified squamous epithelium (200x). **D:** Minor salivary glands, foamy macrophages and extravasated mucin. **E:** Dense connective tissue with chronic inflammatory infiltrate and extravasated mucin.

DISCUSSION.

Mucoceles are common lesions of the oral cavity and may occur in any area of the oral mucosa where salivary glands are present. According to the literature, the highest prevalence of mucocele is on the lower lip (44 to 79% of the cases).^{1,2,4,9,18} Other locations include

the palate, jugal mucosa and the ventral surface of the tongue. In the clinical case presented the lower lip of the patient was also the affected site.

The most common etiology is trauma due to the habit of biting or sucking the lip, which results in a sectioning or obstruction of the secretory duct of salivary

glands, leading to an accumulation or extravasation of mucus.^{1,7,12} In the present clinical case, the legal guardian of the patient reported that her daughter had the habit of sucking the site frequently, culminating with the appearance of the lesion. It is known that the buccal cavity is very prone to small intensity trauma, which is not always considered, evidencing the lack of knowledge of the etiology by the patient's mother when asked during the anamnesis.

There are different treatment choices for oral mucoceles. The most common are excision with a scalpel and electrosurgery. Alternative treatments may also be indicated, such as cryosurgery and CO₂ laser ablation.^{19,22} Micromarsupialization is a treatment option indicated for pediatric or adult patients who cannot undergo surgical procedures, because it is a less traumatic technique, does not require infiltrative anesthesia and is better tolerated by patients.^{13,14}

High-power diode laser treatment is also an option for the removal of a mucocele in pediatric patients because it offers a number of benefits such as excellent hemostasis, without the need for suturing, reduction of edema and pain, faster healing and reduction in the time needed to perform the procedure.^{11,12,15,23}

Despite the existence of more conservative techniques for the treatment of mucoceles, such as micromarsupialization, the optimal treatment continues to be complete enucleation of the lesion, with care to eliminate it and any other lesions, avoiding future recurrences.²⁵ As such this was the treatment of choice in the present clinical case and the material was sent for histopathological analysis.

Histologically, the extravasation-like mucocele presents as a cavity circumscribed by connective tissue

(92% of cases) and submucosal with stretching of the epithelium.

The wall of this cavity is lined by fibrous connective tissue, not by epithelium, giving rise to a pseudocyst. Based on histopathology, the present case was a result of a mucosal lining epithelium (parakeratinized stratified squamous), a lamina propria of dense connective tissue with chronic inflammatory infiltrate and extravasated mucin; granulation tissue delimiting the extravasated mucin area; minor salivary glands and foamy macrophages and extravasated mucin.

Our findings is in agreement with that of Chandramani *et al.*²⁶ Mucocele is the most common among the lesions that affect the soft tissue of the oral cavity, and is found in children of different age groups. It is important that the healthcare professional establish a correct clinical diagnosis, which must be confirmed with a biopsy, aiming at the best and most appropriate treatment for the patient.

CONCLUSION.

The present case report described a case of mucocele caused by sucking inferior lip and the complete enucleation of the lesion proved to be effective without recurrence of the lesion.

Conflict of interests: The authors declare that there is no conflict of interest regarding the publication of this paper.

Ethics approval: Patients gave informed consent.

Funding: Self-funded

Author's contribution: All authors have made substantive contribution to the manuscript.

Acknowledgements: None.

REFERENCES.

1. Nallasivam KU, Sudha BR. Oral mucocele: Review of literature and a case report. J Pharm Bioallied Sci.2015;7:S731-3.
2. Bhargava N, Agarwal P, Sharma N, Agrawal M, Sidiq M, Narain P. An unusual presentation of oral mucocele in infant and its review. Case Rep Dent. 2014;2014:723130.
3. Chaitanya P, Praveen D, Reddy M (2017) Mucocele on Lower Lip: A Case Series. Indian Dermatol Online J 8:205-207.
4. Dent CD, Svirsky JA, Kenny KF. Large mucous retention phenomenon (mucocele) of the upper lip. Case report and review of the literature. Va Dent.1997;J74:8-9.
5. Rashid A, Anwar N, Azizah A, K N. Cases of mucocele treated in the Dental Department of Penang Hospital. Arch Orofac Sci.2008;3:7-10.
6. Nico MM, Park JH, Lourenco SV. Mucocele in pediatric patients: analysis of 36 children. Pediatr Dermatol ;5:308-311.
7. Alves LA, Di Nicolo R, Ramos CJ, Shintome L, Barbosa CS. Retention mucocele on the lower lip associated with inadequate use of pacifier. Dermatol Online. 2010;J 16:9.

8. Ashok Kumar S, Ramakrishnan M. Mucocele in lower lip as a result of improper use of feeding bottle: a case report. *Case Rep Dent.* 2013;2013:520425.
9. Wang WC, Lin LM, Shen YH, Lin YJ, Chen YK. Concurrent extravasation mucocele and epidermoid cyst of the lower lip: a case report. *Kaohsiung J Med Sci.* 2005;21:475-9.
10. Mustapha IZ, Boucree SA, Jr. Mucocele of the upper lip: case report of an uncommon presentation and its differential diagnosis. *J Can Dent Assoc.*2004;70:318-21.
11. Vitale MC, Sfondrini MF, Croci GA, Paulli M, Carbone L, Gandini P, Scribante A. Diode Laser-Assisted Surgical Therapy for Early Treatment of Oral Mucocele in a Newborn Patient: Case Report and Procedures Checklist. *Case Rep Dent.* 2018; 2018:3048429.
12. Agarwal G, Mehra A, Agarwal A (2013) Laser vaporization of extravasation type of mucocele of the lower lip with 940-nm diode laser. *Indian J Dent Res* 24:278.
13. Girardi GB, Saifi AM. Micro-marsupialization versus surgical excision for the treatment of mucoceles. *Ann Maxillofac Surg.*2016;6:204-9.
14. Sagari SK, Vamsi KC, Shah D, Singh V, Patil GB, Saawarn S. Micro-marsupialization: a minimally invasive technique for mucocele in children and adolescents. *J Indian Soc Pedod Prev Dent.*2012;30:188-191.
15. Pedron IG, Galletta VC, Azevedo LH, Correa L. Treatment of mucocele of the lower lip with diode laser in pediatric patients: presentation of 2 clinical cases. *Pediatr Dent.* 2010;32:539-41.
16. Ohta N, Fukase S, Suzuki Y, Aoyagi M. Treatment of salivary mucocele of the lower lip by OK-432. *Auris Nasus Larynx.*2011;38:240-243.
17. Amaral MB, de Freitas JB, Mesquita RA (2012) Upgrading of the micro-marsupialisation technique for the management of mucus extravasation or retention phenomena. *Int J Oral Maxillofac Surg.* 2012;41:1527-31.
18. Oka M, Nishioka E, Miyachi R, Terashima M, Nishigori C. Case of superficial mucocele of the lower lip. *J Dermatol .* 2007;34:754-756.
19. Baurmash HD (2003) Mucoceles and ranulas. *J Oral Maxillofac Surg.* 2003;61:369-78.
20. Huang IY, Chen CM, Kao YH, Worthington P. Treatment of mucocele of the lower lip with carbon dioxide laser. *J Oral Maxillofac Surg.*2007;65:855-8.
21. Jones AV, Franklin CD. An analysis of oral and maxillofacial pathology found in children over a 30-year period. *Int J Paediatr Dent.* 2006;16:19-30.
22. Kopp WK, St-Hilaire H. Mucosal preservation in the treatment of mucocele with CO2 laser. *J Oral Maxillofac Surg.* 2004; 62:1559-1561.
23. Boj JR, Poirier C, Espasa E, Hernandez M, Espanya A. Lower lip mucocele treated with an erbium laser. *Pediatr Dent .* 2019;31:249-52.
24. Ramkumar S, Ramkumar L, Malathi N, Suganya R. Excision of Mucocele Using Diode Laser in Lower Lip. *Case Rep Dent.* 2016; 2016:1746316.
25. Di Lauro AE, Abbate D, Dell'angelo B, Di Lauro F, Sammartino G. Treatment of a post surgery defect of the lower lip: a case report. *Minerva Stomatol.* 2010;59:663-669.
26. More CB, Bhavsar K, Varma S, Tailor M. Oral mucocele: A clinical and histopathological study. *J Oral Maxillofac Pathol.*2014;18:S72-77.