

Comparison of the anti-inflammatory effectiveness of dexamethasone as pre-surgical and post-surgical therapy in mandibular third molar surgery: A randomized clinical trial.

Comparación de la efectividad antiinflamatoria de dexametasona como terapia prequirúrgica y postquirúrgica en la cirugía del tercer molar mandibular. Ensayo clínico aleatorizado.

Daniella Núñez-Díaz.¹
Victor Chumpitaz-Cerrate.²
Lesly Chávez-Rimache.¹
Luis German-Santa Cruz.³

Affiliations: ¹Facultad de Odontología, Universidad Nacional Mayor de San Marcos, Lima, Perú.²Laboratorio de Farmacología, Facultad de Ciencias de la Salud, Universidad Científica del Sur, Lima, Perú.³Departamento Académico de Estomatología Médico Quirúrgica, Facultad de Odontología, Universidad Nacional Mayor de San Marcos, Lima, Perú.

Corresponding author: Victor Chumpitaz-Cerrate. Carr. Panamericana Sur 19, Villa EL Salvador 15067, Peru. Phone: (51) 992779274. Email: vchumpitaz@ucientifica.edu.pe

Receipt: 01/11/2019 **Revised:** 05/28/2019
Acceptance: 07/20/2019 **Online:** 12/30/2019

Cite as:

Núñez-Díaz D, Chumpitaz-Cerrate V, Chávez-Rimache L & German-Santa Cruz L. Comparison of the anti-inflammatory effectiveness of dexamethasone as pre-surgical and post-surgical therapy in mandibular third molar surgery: A randomized clinical trial. *J Oral Res* 8(6):463-470.
Doi:10.17126/joralres.2019.068

Abstract: Objective: To compare the anti-inflammatory effectiveness of dexamethasone as pre-surgical and post-surgical therapy in mandibular third molar surgery. Materials and methods: Randomized clinical trial conducted in 60 patients in need of mandibular third molar extraction, ages ranging from 16 to 35 years old, at the Department of Oral and Maxillofacial Surgery of the Arzobispo Loayza National Hospital during the period of January-March, 2016. Patients were distributed in two randomized groups: Group A received 4mg dexamethasone intramuscular before the surgery, and Group B received the same medication post-surgery. Facial edema was assessed using the distance between facial points, trismus was evaluated using the interincisal distance, and pain intensity was determined using a Numerical Scale (NS). Results: Facial edema values were lower in Group A at 60 minutes ($p=0.002$) and after the first ($p=0.001$) and third days ($p=0.009$), compared to Group B. Regarding trismus, no significant differences between the groups were found. Regarding pain intensity, the highest point was recorded at 6 hours in both groups; however, no significant differences between the groups were found. Conclusion: Pre-surgical dexamethasone administration produced a significantly greater reduction in facial edema after mandibular third molar surgery.

Keywords: Dexamethasone; anti-inflammatory agents; surgery, oral; third molar; edema; pain.

Resumen: Objetivo: Comparar la efectividad antiinflamatoria de dexametasona como terapia prequirúrgica y postquirúrgica en la cirugía del tercer molar mandibular. Materiales y métodos: Ensayo clínico aleatorizado que incluyó a 60 pacientes de 16 a 35 años del Servicio de Cirugía Bucal y Maxilofacial del Hospital Nacional Arzobispo Loayza con necesidad de exodoncia de tercer molar mandibular durante el periodo de enero a marzo del 2016. Se distribuyeron en dos grupos aleatoriamente: El grupo A recibió prequirúrgicamente 4 mg de dexametasona vía intramuscular y el grupo B recibió la misma medicación postquirúrgicamente. Se evaluó el edema facial, mediante la distancia entre puntos faciales, el trismus mediante la distancia interincisal y la intensidad de dolor mediante la Escala Numérica (EN). Resultados: Los valores del edema facial fueron menores en el grupo A a los 60 minutos ($p=0,002$), primer ($p=0,001$) y tercer día ($p=0,009$) en comparación al grupo B. Respecto al trismus, no se encontró diferencia significativa entre los grupos durante las evaluaciones realizadas. Respecto al dolor, la mayor intensidad se percibió a las 6 horas en ambos grupos; sin embargo, no se encontró diferencia significativa entre los grupos durante todas las evaluaciones realizadas. Conclusión: La administración prequirúrgica de dexametasona produjo una significativa mayor reducción del edema facial posterior a la cirugía del tercer molar mandibular.

Palabras Clave: Dexametasona; agentes antiinflamatorios; cirugía oral; tercer molar; edema; dolor.

INTRODUCTION.

The mandibular third molar is the tooth with the highest frequency of eruption alterations. Therefore, its extraction is one of the most frequent procedures in oral surgery.^{1,2} Mandibular third molar surgery causes a number of postoperative complications, generated by the surgical procedures performed during the intervention (incision, flap lift, osteotomy and tooth sectioning). For this reason, there is a great release of inflammatory mediators such as histamine, bradykinin and prostaglandins, intensifying the inflammatory process.³⁻⁶

The most frequent postoperative complications are edema, trismus (a consequence of the swelling and contracture of masticatory muscles) and pain. These complications lead to an uncomfortable situation for the patient, hindering or even impeding daily activities.^{7,8} Pharmacotherapy, conducted with the objective of reducing complications caused by surgical trauma, is directed towards prevention and reduction of the inflammatory process. Administering corticosteroids is recommended after performing various surgical procedures, including mandibular third molar extractions, in order to reduce facial edema.^{6,9}

Some authors recommend an intramuscular corticosteroid dose 30 minutes before the surgical procedure, while others suggest that the administration should be into the masseter muscle, in the immediate post-surgical period. In both cases, the most commonly used corticosteroid is dexamethasone, due to its anti-inflammatory effectiveness and accessibility.^{9,10} If the patient does not accept the parenteral route for corticosteroid administration, the oral route is an option.⁴ The literature recommends 8mg dexamethasone, 1 hour before the surgical procedure.^{10,11}

These protocols are based on numerous clinical trials; however, there is insufficient scientific evidence to reach a consensus regarding the anti-inflammatory effectiveness of dexamethasone in mandibular third molar surgery, when using the same dose and route at different administration times. Considering the above, the aim of the present research was to compare the anti-inflammatory effectiveness of dexamethasone as pre-surgical and post-surgical therapy in mandibular third molar surgery.

MATERIALS AND METHODS.

A parallel, double-blind, single-center randomized clinical trial was conducted according to the CONSORT guidelines (Figure 1). Participants consisted of 64 young adults, 42 females and 22 males, all candidates for surgical extraction of mandibular third molars at the Department of Oral and Maxillofacial Surgery of the Arzobispo Loayza National Hospital, in the period January-March of 2016.

The simple random sampling method was employed. In order to determine sample size, the swelling variable was considered, with a confidence level of 95%, a 4.8mm difference, a standard deviation of 3.02, and a statistical power of 80%.³

The study protocols, as well as the informed consent and assent agreements, were developed according to the Declaration of Helsinki, and approved by the ethics committees of the School of Medicine of Universidad Nacional Mayor de San Marcos (No. 0234) and the Arzobispo Loayza National Hospital (No. 026).¹²

The patients under 18 years of age were asked to provide informed assents, while their parents signed informed consents. Participants over 18 years of age signed the informed consent form that was approved by the ethics committees, adhering to universal ethical principles such as autonomy, justice, generosity and non-maleficence.

The inclusion criteria considered young adults aged 16 to 35 years, ASA I, who were in need of non-erupted mandibular third molar surgery, and were not allergic to non-steroidal anti-inflammatory drugs (NSAIDs), paracetamol, corticosteroids and local anesthetics.

Exclusion criteria included patients with any sort of dentoalveolar or periodontal pathology, those with physical or mental disability, those who had taken any medication in the last 14 days, smokers, and women who were pregnant or breastfeeding.

Patients were randomly distributed in two groups using the random number table method. Subsequently, medications that were to be administered were designated and distinguished with red and blue packaging for groups A and B, respectively.

Group A was given 4mg intragluteal injection of dexamethasone (Dexacort®) 30 minutes before surgery. Group B was also given 4mg intragluteal injection of dexamethasone (Dexacort®) immediately after surgery.

Before performing the surgical procedure, the Gbotolorun index was determined in order to assess the degree of surgical difficulty, considering parameters such as age, body mass index, and depth from point of elevation and root curvature.

All surgical procedures were performed by a single surgeon, who used a standardized technique and was unaware of the type of medication administered to the patients.⁶ Surgery was performed according to the established extraction protocols for retained mandibular third molars. First, asepsis and antisepsis were carried out using povidone-iodine, then, local anesthesia was administered using 2% lidocaine with 1:80000 epinephrine (Xylestesin™-A) via the truncal technique for the inferior and lingual dental nerves, and employing the infiltrating technique of the buccal nerve.

A marginal sulcular incision was made with a No.15 scalpel, and the mucoperiosteal flap lifted. Afterwards, osteotomy and tooth sectioning were performed using a No.0541 26mm surgical fissure drill (Dentsply Maillefer), followed by profuse rinsing using saline, subsequently repositioning the flap. The surgery finished with tissue hemostasis and suturing using 3.0 sharp tip black silk suture. After surgery, patients received verbal and written instructions, along with post-surgical pharmacotherapy prescriptions for 50mg diclofenac + 500mg paracetamol (Dololiviolex Forte®), orally every 8 hours for 4 days, and for 500mg amoxicillin (Velamox®), orally every 8 hours for 5 days.

An independent researcher, blinded and calibrated, carried out all the measurements. Calibration was performed in 20 patients, accompanied by an expert (oral maxillofacial surgeon). The interclass correlation coefficient (ICC) was 0.91 for edema, and 0.89 for mouth opening evaluation.

Facial edema

Measuring tapes were used to follow facial point trajectories: gonion-tragus, gonion-exocantion, gonion-alar, gonion-quelion and gonion-gnation. Pre-surgical measurements were taken on the facial side where surgery would be performed. Post-surgical measurements were taken after 60 minutes and on the first, third and seventh day after the surgery. Afterwards, measurements were made using an electronic Vernier caliper. For the overall

facial edema assessment, the sum of all differences of post-surgical and pre-surgical measurements were considered.

Trismus

For trismus assessment, the distance between the incisal edges of teeth 11 to 41, or 21 to 31, was measured using an electronic Vernier caliper. This evaluation was performed in the preoperative period, followed by measurements after 60 minutes and on the first, third and seventh day after the surgery. For the evaluation of trismus, post-surgical and pre-surgical measurement differences were considered.

Pain intensity

A numerical scale was used to evaluate pain intensity. The patient reported a numerical value between two extreme points (0-10) that indicated the severity of pain, with points in the scale describing the following: 0 (Zero) absence of pain, and 10 (Ten) the maximum imaginable pain. This evaluation was carried out in the postoperative period at the first and sixth hour after surgery, as well as on the first, third and seventh post-surgical days.

Data analysis

Data was interpreted and analyzed using SPSS statistical software (version 24.0). The normality of variables was assessed using the Shapiro-Wilk test. The Mann-Whitney U test was used for the comparison of non-parametric quantitative variables, and the Wilcoxon test was used for intragroup analysis.

RESULTS.

From the total number of participants (n=64), 3 did not follow the given instructions and 1 dropped out of the study due to travel-related reasons (Figure 1). The resulting sample (n=60) consisted of 20 males and 40 females, equally distributed among both groups. Average age was 21.62 ± 1.72 years (Table 1). According to the Gbotolorun index, the average degree of surgical difficulty was 7.23, implying moderate difficulty, with no significant difference between the two groups.^{13,14}

Facial edema

Facial edema in Group A at 60 minutes post-surgery was $4.3\text{mm} \pm 1.64\text{mm}$ (95% CI=2.6 - 5.9), and $6.7\text{mm} \pm 2.13\text{mm}$ (CI 95 %=5.3 - 8.14) in Group B; $p=0.002$.

On the first day after surgery edema increased in both groups: $7.1\text{mm} \pm 2.46\text{mm}$ (95% CI= 5 - 9.3) in Group A, and $12.13\text{mm} \pm 2.85\text{mm}$ (95% CI= 9.1 - 15.07) in Group

B; $p=0.001$. On the third day, edema was at its highest in both groups: $10.17\text{mm} \pm 3.84\text{mm}$ (95% CI=6.9 - 13.5) in Group A, and $15.24\text{mm} \pm 3.05\text{mm}$ (95% CI=12.38 - 17.89); $p=0.009$ in Group B (Table 2).

Intragroup analysis yielded significant differences between all the pairs of measurements evaluated, except for the comparison between 60 minutes and 7 days post-surgery, for Group A ($p=0.45$) and group B ($p=0.92$).

Trismus

Trismus evaluation at 60 minutes after undergoing surgery showed the following results: $5.05\text{mm} \pm 2.10\text{mm}$ (95% CI=2.7 - 7.39) in Group A, and $3.8\text{mm} \pm 1.97\text{mm}$ (CI 95% = 1.61-5.27) in Group B; $p=0.9$.

On the third day, trismus was $6.4\text{mm} \pm 1.56\text{mm}$ (95% CI=4.18 - 7.34) in Group A, and $6.1\text{mm} \pm 2.91\text{mm}$ in Group B (95% CI=3.9-8.8); $p=0.88$. On the seventh day, trismus was 0.61 ± 0.37 mm (95% CI=0.09 - 1.14) in Group A, and 2.14 ± 0.91 mm (CI 95%=0.37 - 3.92) in Group B; $p=0.21$ (Table 3).

Intragroup analysis showed significant differences between all the pairs of measurements evaluated in Group A, except for the comparison between the first and third

day ($p=0.95$). In Group B, results showed significant differences among all the pairs of measurements evaluated, except for comparisons between the 60 minute and seven-day periods ($p=0.092$), and the first and third day after surgery ($p=0.56$).

Pain intensity

Pain intensity recorded 60 minutes post-surgery in Group A was $0.94\text{mm} \pm 0.29\text{mm}$ (95% CI=0.32 - 1.55), and $0.83\text{mm} \pm 0.21\text{mm}$ in Group B (95% CI=0.42 - 1.25); $p=0.621$.

After 6 hours, the highest degree of pain intensity was documented in both groups; 1.47 ± 0.78 (95% CI=0.88 - 2.06) in Group A, and 1.77 ± 0.86 (95% CI=0.91 - 2.10) in Group B; $p=0.263$.

On the first day, the recorded pain intensity in Group A was 0.91 ± 0.07 (95% CI=0.87 - 0.97), while in Group B it was 1.07 ± 0.29 (95% CI=0.96 - 1.23); $p=0.18$.

On the third day, pain intensity in Group A was $1.19\text{mm} \pm 0.21\text{mm}$ (95% CI=1.08 - 1.34), and was $1.47\text{mm} \pm 0.13\text{mm}$ (95% CI=1.31 - 1.72) in Group B; $p=0.23$ (Table 4). Intragroup analysis showed no significant differences between all the pairs of measurements evaluated.

Figure 1. Flow chart of patient recruitment in this study according to the CONSORT guidelines.

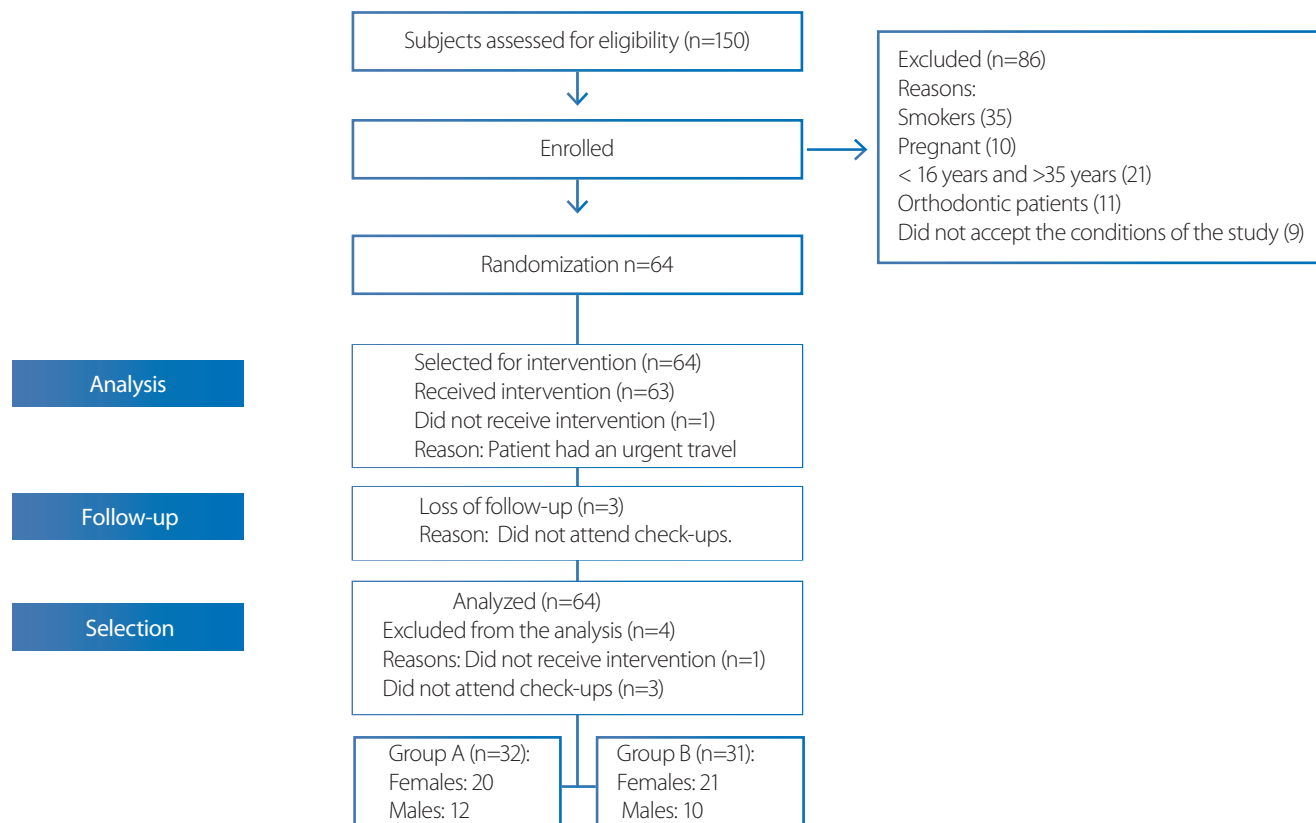


Table 1. Demographic data of the patients according to group.

| | Group A | Group B | Total |
|---------|--------------|--------------|--------------|
| Females | 19 | 21 | 40 |
| Males | 13 | 10 | 20 |
| Age | 22.07 ± 1.41 | 20.54 ± 1.35 | 21.62 ± 1.72 |

Table 2. Facial edema according to group.

| Measurement of facial edema | Group A | | | | | Group B | | | | | p-value |
|-----------------------------|---------|------|-------|------|------------|---------|------|-------|------|-------------|---------|
| | Mean | SD | Max | Min | CI | Mean | SD | Max | Min | CI | |
| 60 minutes | 4.3 | 1.64 | 6.8 | 2.18 | 2.6 – 5.9 | 6.7 | 2.13 | 9.15 | 4.67 | 5.3 – 8.14 | 0.002 |
| First day | 7.1 | 2.46 | 10.4 | 4.12 | 5 – 9.3 | 12.13 | 2.85 | 16.23 | 8.65 | 9.1 – 15.07 | 0.001 |
| Third day | 10.17 | 3.84 | 16.89 | 5.78 | 6.9 – 13.5 | 15.24 | 3.05 | 18.1 | 11.2 | 12.3 – 17.8 | 0.009 |
| Seventh day | 3.92 | 1.91 | 6.54 | 2.14 | 2.7 – 5.09 | 6.60 | 2.42 | 9.62 | 3.8 | 4.15 – 9.05 | 0.052 |

SD: Standard deviation. CI: Confidence interval.

Table 3. Trismus evaluation according to group.

| Trismus | Group A | | | | | Group B | | | | | p-value |
|-------------|---------|------|-------|------|--------------|---------|------|-------|------|-------------|---------|
| | Mean | SD | Max | Min | CI | Mean | SD | Max | Min | CI | |
| 60 minutes | 5.05 | 2.10 | 8.13 | 2.54 | 2.7 – 7.39 | 3.8 | 1.97 | 6.14 | 1.15 | 1.61 – 5.27 | 0.9 |
| First day | 9.1 | 4.02 | 15.42 | 4.04 | 4.16 – 14.16 | 7.2 | 1.94 | 10.02 | 4.31 | 4.8 – 9.7 | 0.98 |
| Third day | 6.4 | 1.56 | 7.59 | 4.14 | 4.18 – 7.34 | 6.1 | 2.91 | 9.12 | 2.91 | 3.9 – 8.8 | 0.88 |
| Seventh day | 0.61 | 0.37 | 2.01 | 0.02 | 0.09 – 1.14 | 2.14 | 0.91 | 4.13 | 0.23 | 0.37 – 3.92 | 0.21 |

Table 4. Intensity of postsurgical pain according to group.

| Trismus | Group A | | | | | Group B | | | | | p-value |
|-------------|---------|-------|------|------|-------------|---------|------|------|------|-------------|---------|
| | Mean | SD | Max | Min | CI | Mean | SD | Max | Min | CI | |
| 60 minutes | 0.94 | 0.29 | 2.3 | 0.12 | 0.32 – 1.55 | 0.83 | 0.21 | 1.37 | 0.39 | 0.42 – 1.25 | 0.621 |
| 6 hours | 1.47 | 0.78 | 3.15 | 0.39 | 0.88 – 2.06 | 1.77 | 0.86 | 2.18 | 0.81 | 0.91 – 2.10 | 0.263 |
| First day | 0.91 | 0.07 | 1.12 | 0.31 | 0.87 – 0.97 | 1.07 | 0.29 | 1.56 | 0.78 | 0.96 – 1.23 | 0.18 |
| Third day | 1.19 | 0.21 | 2.16 | 0.95 | 1.08 – 1.34 | 1.47 | 0.13 | 2.01 | 1.02 | 1.31 – 1.72 | 0.23 |
| Seventh day | 0.09 | 0.023 | 0.6 | 0.02 | 0.07 – 0.1 | 0.17 | 0.05 | 0.28 | 0.05 | 0.15 – 0.19 | 0.31 |

DISCUSSION.

Prevention or reduction of the inflammatory process after third molar surgery justifies the prescription of various drugs such as NSAIDs, corticosteroids and opioids. Multiple clinical trials have shown that the effect of corticosteroids in the control of complications after third molar surgery is superior to that of NSAIDs.^{11,15,16}

Dexamethasone has two mechanisms of action that inhibit the inflammatory process. The first one is a genomic mechanism (slow-acting) that involves the diffusion of corticosteroid molecules through the cell membrane and binding with the cytosolic receptors GR- α and GR- β for

their subsequent transport to the nucleus, where they bind to specific DNA sequences and promote the expression of mRNA and subsequent synthesis of anti-inflammatory proteins.¹⁷⁻²⁰

The second one is a non-genomic (fast-acting) mechanism that involves dexamethasone binding with cell membrane receptors, resulting in the formation of second messengers such as cAMP or protein kinases, which inhibit the expression of phospholipase-A2 and COX-2 enzymes.¹⁸⁻²³ For this reason, dexamethasone was chosen because of its great anti-inflammatory effectiveness, long half-life and causes no sodium retention. In addition,

the intramuscular route was chosen for its accessibility, fast acting capabilities and greater control of the inflammatory process in mandibular third molar surgery.^{3-5,16}

The surgical difficulty index and the duration of the procedure are related to each other and, in turn, to surgical trauma, favoring the postoperative inflammatory process.^{13,14} In this research, there was no significant difference in the surgical difficulty index between both groups, meaning these parameters did not affect the results.

In this study, pre-surgical intramuscular administration of dexamethasone resulted in a significant decrease in edema compared to post-surgical administration at one hour, and on the first and third post-surgical days.

These results are similar to those reported by Graziani *et al.*,²⁴ Lima *et al.*,¹⁶ and Al-Shamiri *et al.*,²⁵ which showed that pre-surgical oral administration of 8mg dexamethasone produced a significantly greater reduction in swelling compared to postoperative administration after the first hour, and on the first and third post-surgical days.

On the other hand, in their systematic review, Fernandes *et al.*,⁴ found no difference in swelling between preoperative and immediate postoperative administration of dexamethasone. A reason for this could be that the studies included used different administration routes (oral, intramuscular and submucosal). However, there is ongoing controversy regarding the benefits of preoperative medication. In this study, results showed edema increased from 60 minutes post-surgical, reaching its maximum level on the third post-operative day, and then decreasing gradually. This corroborates what has been theoretically established and coincides with the data reported in other studies.²⁶⁻²⁸

Results showed less trismus in the group treated with post-surgical dexamethasone in the first three postoperative evaluations, outcome that was reverted on the seventh day. However, these differences were not significant, coinciding with the clinical trials conducted by Moore *et al.*,²⁹ which showed that the group that received preoperative rofecoxib and intraoperative dexamethasone had a mouth opening reduction of only 23.7%, compared to the placebo group, which showed a 43.2% reduction; $p > 0.05$. Al-Shamiri *et al.*,²⁵ reported that the group of post-surgical dexamethasone recorded higher mouth opening levels on the second day evaluation

(34.6mm±8.2mm), compared to the preoperatively medicated group (32.2mm ± 5.7mm); $p = 0.412$.

These results coincide with clinical trials conducted by Klongnoi *et al.*,³ in a split mouth model of mandibular third molar surgery, as their conclusions did not find a significant difference in trismus levels between the group treated with preoperative dexamethasone, evaluated after the second (45.2mm±4.27mm) and seventh post-surgical day (45.4mm±4.22mm), compared to the control group (43.5mm±4.21mm and 45.6mm ± 4.30mm; respectively); $p = 0.12$ on the second day, and $p = 0.47$ on the seventh day. In this study, the highest levels of trismus for both groups were recorded on the first post-surgical day, resolved almost entirely by the seventh day, a similar outcome to that reported by various studies.²⁷⁻³⁰

Results showed that a higher degree of pain was recorded in the group that received pre-surgical dexamethasone compared to the post-surgical group, at 60 minutes after surgery. The reversed was observed after the 6-hour evaluation until the seventh post-surgical day. These results can be explained by the pharmacokinetic attributes of dexamethasone and its genomic mechanism of action, which are enhanced with the passage of time. No significant differences were found in pain intensity assessments, indicating similarities regarding the analgesic effect for both timings of medication administration. However, in most of the evaluations performed, a lower pain intensity degree was observed in the group that received preoperative dexamethasone.

In their systematic review, Falci *et al.*,¹¹ report that preventive use of NSAIDs does not significantly reduce postoperative pain in third molar surgery compared to corticosteroids such as dexamethasone, because of the latter's anti-inflammatory effectiveness. Likewise, they describe that preventive corticosteroid analgesia is based on its mechanism of action, as it affects the initial stage of inflammatory response. Inhibition of phospholipase A2 reduces arachidonic acid release, decreasing the levels of vasoactive substances: prostaglandins and leukotrienes.^{4,6}

These results differ with Al-Shamiri *et al.*,²⁵ as their study showed that preoperative dexamethasone medication increased its analgesic effect, according to the VAS, and achieved significantly higher efficacy on the third day (2.6mm ± 1.5mm), compared to the group that received

postoperative dexamethasone ($3.2\text{mm} \pm 1.5\text{mm}$); $p=0.008$. Similarly, Boonsiriseth *et al.*,²⁸ reported a similar analgesic effect on the first day after immediate post-surgical administration of intramuscular ($20.8\text{mm} \pm 21.3\text{mm}$) and oral ($22.4\text{mm} \pm 24\text{mm}$) dexamethasone, increasing progressively until the seventh postoperative day ($2.2\text{mm} \pm 5.5\text{mm}$ and $4.7\text{mm} \pm 1.21\text{mm}$; respectively); $p>0.05$. In this study, the highest degree of postoperative pain intensity was recorded 6 hours after the surgical procedure, resolving almost completely by the seventh day; confirming what has been reported in various studies.^{11,17,20} Limitations of this study include the realization that a patient's facial pattern type (mesofacial, dolichofacial and brachifacial) is important in order to standardize facial edema and obtain more accurate results, either by taking photographs or via radiographic analysis. In this study, postoperative and preoperative measurements and their differences were used in order to diminish the effect of this limitation.

CONCLUSION.

In mandibular third molar surgery, pre-surgical dexamethasone administration produced a significantly greater decrease in facial edema compared to post-surgical administration. There were no significant differences between both groups regarding trismus and post-surgical pain intensity.

REFERENCES.

1. Vegas-Bustamante E, Mico-Llorens J, Gargallo-Albiol J, Satorres-Nieto M, Berini-Aytes L, Gay-Escoda C. Efficacy of methylprednisolone injected into the masseter muscle following the surgical extraction of impacted lower third molars. *Int J Oral Maxillofac Surg.* 2008;37:260-3.
2. Larsen MK, Kofod T, Christiansen A-E, Starch-Jensen T. Different Dosages of Corticosteroid and Routes of Administration in Mandibular Third Molar Surgery: a Systematic Review. *J Oral Maxillofac Res.* 2018;9(2):e1.
3. Klongnoi B, Kaewpradub P, Boonsiriseth K, Wongsirichat N. Effect of single dose preoperative intramuscular dexamethasone injection on lower impacted third molar surgery. *Int J Oral Maxillofac Surg.* 2012;41(3):376-9.
4. Fernandes IA, de Souza GM, Pinheiro MLP, Falci SGM. Intramuscular injection of dexamethasone for the control of pain, swelling, and trismus after third molar surgery: a systematic review and meta-analysis. *Int J Oral Maxillofac Surg.* 2018;48(5):659-668.
5. Moraschini V, Hidalgo R, Porto Barboza E dS. Effect of submucosal injection of dexamethasone after third molar surgery: a meta-analysis of randomized controlled trials. *Int J*

Conflict of interests: The authors declare no conflict of interest of any kind.

Ethics approval: This study was evaluated and approved by ethics committees of the School of Medicine of Universidad Nacional Mayor de San Marcos (No. 0234) and the Arzobispo Loayza National Hospital (No. 026).

Funding: Self-funded

Author's contribution: Núñez D, Chávez L and Chumpitaz-Cerrate V wrote the manuscript. Núñez D performed data collection. Chávez L performed statistical analyses. Chumpitaz-Cerrate V analyzed and interpreted the data. Santa Cruz L contributed towards the literature revision.

Acknowledgements: To the Department of Oral and Maxillofacial Surgery of the National Hospital Archbishop Loayza for its collaboration in the execution of this study, and to the following oral and maxillofacial surgeons: Barría Angulo, Hosting; Oré de la Cruz, Jhames.

6. Alcântara CEP, Falci SGM, Oliveira-Ferreira F, Santos CRR, Pinheiro MLP. Pre-emptive effect of dexamethasone and methylprednisolone on pain, swelling, and trismus after third molar surgery: a split-mouth randomized triple-blind clinical trial. *Int J Oral Maxillofac Surg.* 2014;43(1):93-8.
7. Herrera-Briones FJ, Prados Sánchez E, Reyes Botella C, Vallecillo Capilla M. Update on the use of corticosteroids in third molar surgery: systematic review of the literature. *Oral Surg Oral Med Oral Pathol Oral Radiol.* 2013;116(5):e342-51.
8. Barbalho JC, Vasconcellos RJ, de Moraes HH, Santos LA, Almeida RA, Rêbello HL, Lucena EE, de Araújo SQ. Effects of co-administered dexamethasone and nimesulide on pain, swelling, and trismus following third molar surgery: a randomized, triple-blind, controlled clinical trial. *Int J Oral Maxillofac Surg.* 2017;46(2):236-42.
9. Dereci O, Tuzuner-Oncul AM, Kocer G, Yuce E, Askar M, Oztuk A. Efficacy of immediate postoperative intramasseteric dexamethasone injection on postoperative swelling after mandibular impacted third molar surgery: A preliminary split-mouth study. *J Pak Med Assoc.* 2016;66(3):320-3.

10. Paiva-Oliveira JG, Bastos PR, Cury Pontes ER, da Silva JC, Delgado JA, Oshiro-Filho NT. Comparison of the anti-inflammatory effect of dexamethasone and ketorolac in the extractions of third molars. *Oral Maxillofac Surg.* 2016;20(2):123-33.
11. Falci S, Lima T, Martins C, Santos C, Pinheiro M. Preemptive Effect of Dexamethasone in Third-Molar Surgery: A Meta-Analysis. *Anesth Prog.* 2017; 64(3):136-43.
12. General Assembly of the World Medical Association. World Medical Association Declaration of Helsinki: ethical principles for medical research involving human subjects. *J Am Coll Dent.* 2014;81(3):14-8.
13. R de Carvalho RWF, Vasconcelos BC. Pernambuco index: predictability of the complexity of surgery for impacted lower third molars. *Int J Oral Maxillofac Surg.* 2018;47(2):234-40.
14. Gbotolorun OM, Arotiba GT, Ladeinde AL. Assessment of factors associated with surgical difficulty in impacted mandibular third molar extraction. *J Oral Maxillofac Surg.* 2007;65(10):1977-83.
15. Relief of complications after third molar surgery. *Dental Abstracts.* 2018;63(4): 244-5.
16. Lima TC, Bagordakis E, Falci SG, Dos Santos CR, Pinheiro ML. Pre-emptive effect of dexamethasone and diclofenac sodium associated with codeine on pain, swelling, and trismus after third molar surgery: a split-mouth randomized triple-blind controlled clinical trial. *J Oral Maxillofac Surg.* 2018;76(1):60-6.
17. Ahmed Mohamed El Zayat, Eman Abdelhalem El Sharrawy, Amr Ali El Swify, Abdel Bade Abd Allah Abdel Maabod. Comparative Clinical Study of Local Submucosal Corticosteroid Versus Diclofenac Sodium Injections Before Odontectomy of Mandibular Impacted Third Molar. *Int J Oral Maxillofac Surg.* 2018;4(1):19-24.
18. Almeida RAC, Lemos CAA, de Moraes SLD, Pellizzer EP, Vasconcelos BC. Efficacy of corticosteroids versus placebo in impacted third molar surgery: systematic review and meta-analysis of randomized controlled trials. *Int J Oral Maxillofac Surg.* 2018.48(1):118-31
19. Al-Dajani, M. Can preoperative intramuscular single-dose dexamethasone improve patient-centered outcomes following third molar surgery? *J Oral and Maxillofac Surg.* 2017;75(8):1616-26.
20. Troiano G, Laino L, Cicciù M, Cervino G, Fiorillo L, D'amico C, et al. Comparison of Two Routes of Administration of Dexamethasone to Reduce the Postoperative Sequelae After Third Molar Surgery: A Systematic Review and Meta-Analysis. *Open Dent J.* 2018;12:181-8.
21. Koçer G, Yuce E, Tuzuner Oncul A, Dereci O, Koskan O. Effect of the route of administration of methylprednisolone on oedema and trismus in impacted lower third molar surgery. *Int J Oral Maxillofac Surg.* 2014;43(5):639-43.
22. Afkan S, Mofateh M, Razavi M, Kazemi P. Clinical Evaluation of Dexamethasone Pills on Side Effects of Mandibular Third Molars Surgery. *J Res Med Dent Sci.* 2018; 6 (1): 98-106.
23. Rocha-Neto AM, Nogueira EF, Borba PM, Laureano-Filho JR, Vasconcelos BC. Application of Dexamethasone in the Masseter Muscle During the Surgical Removal of Lower Third Molars. *J Craniofac Surg.* 2017; 28(1):e43-e47.
24. Graziani F, D'Aiuto F, Arduino PG, Tonelli M, Gabriele M. Perioperative dexamethasone reduces post-surgical sequelae of wisdom tooth removal. A split-mouth randomized double-masked clinical trial. *Int J Oral Maxillofac Surg.* 2006; 35:241-247.
25. Al-Shamiri HM, Shawky M, Hassanein N. Comparative Assessment of Preoperative versus Postoperative Dexamethasone on Postoperative Complications following Lower Third Molar Surgical Extraction. *Int J Dent.* 2017;2017:1350375.
26. Bortoluzzi MC, Capella DL, Barbieri T, Pagliarini M, Cavalieri T, Manfro R. A single dose of amoxicillin and dexamethasone for prevention of postoperative complications in third molar surgery: a randomized, double-blind, placebo controlled clinical trial. *J Clin Med Res.* 2013;5(1):26-33.
27. King K, Brar P, Jakubowski J, Kaltman S, Lopez E. The use of corticosteroids and nonsteroidal antiinflammatory medication for the management of pain and inflammation after third molar surgery: a review of the literature. *Oral Surg Oral Med Oral Pathol Oral Radiol Endod.* 2009;107(5):630-40.
28. Boonsiriset K, Klgnoi B, Sirintawat N, Saengsinavin, C, Wongsirichat N. Comparative study of the effect of dexamethasone injection and consumption in lower third molar surgery. *Int J Oral Maxillofac Surg.* 2012;41(2):244-7.
29. Moore PA, Brar P, Smiga ER, Costello BJ. Preemptive rofecoxib and dexamethasone for prevention of pain and trismus following third molar surgery. *Oral Surg Oral Med Oral Pathol Oral Radiol Endod.* 2005;99(2):E1-7.
30. Lim D, Ngeow WC. A comparative study on the efficacy of submucosal injection of dexamethasone versus methylprednisolone in reducing postoperative sequelae following third molar surgery. *J Oral Maxillofac Surg.* 2017;75(11):2278-86.