

Effect of facemask protraction on the development of impacted maxillary canines: a retrospective study.

Efecto de la prolongación de la máscara facial en el desarrollo de los caninos maxilares impactados: un estudio retrospectivo.

Michele Tepedino.¹
Graziano Montaruli.²
Maciej Iancu Potrubacz.¹
Letizia Perillo.³
Claudio Chimenti.¹
Domenico Ciavarella.²

Affiliations: ¹Department of Biotechnological and Applied Clinical Sciences, University of L'Aquila, L'Aquila, Italy. ²Department of Clinical and Experimental Medicine, University of Foggia, Foggia, Italy. ³Multidisciplinary Department of Medical-Surgical and Dental Specialties, Second University of Naples, Naples, Italy.

Corresponding author: Michele Tepedino. Depto. of Biotechnological and Applied Clinical Sciences, University of L'Aquila. V.le S.Salvatore, Edificio Delta 6, 67100 L'Aquila, AQ, Italy. Phone: (39) 0862434782. Email: m.tepedino@hotmail.it

Receipt: 02/22/2019 **Revised:** 04/30/2019
Acceptance: 05/17/2019 **Online:** 12/29/2019

Cite as:

Tepedino M, Montaruli G, Iancu Potrubacz M, Letizia Perillo L, Chimenti C & Ciavarella D. Effect of facemask protraction on the development of impacted maxillary canines: a retrospective study.
J Oral Res 8(5):350-355.
Doi:10.17126/joralres.2019.054

Abstract: Objective: The aim of the present study was to evaluate if maxillary protraction with facemask increases the risk of maxillary canine impaction. Materials and method: The records of 76 skeletal Class III subjects with a cervical vertebral maturation stage between CS1 and CS3 and a displaced maxillary canine were retrospectively collected. Intraoral photographs, orthopantomography and lateral cephalograms were collected, and patients were divided into three groups depending on the type of treatment received – a Rapid Palatal Expander (RPE), a RPE in conjunction with a facemask (RPE-FM), or a Class III functional appliance (FA). The patient's records were used to determine if the maxillary canines were correctly erupted after that phase of treatment. A binary logistic regression was used to evaluate the effect of treatment modality and skeletal maturation stage on the chance of maxillary canine impaction. Results: No effect of the three different treatment modalities and of the skeletal maturation stage on the risk of canine impaction was observed. Conclusions: The protraction facemask can be used in growing skeletal Class III subjects without increasing the risks of maxillary canine displacement.

Keywords: Corrective orthodontics; canine tooth; impacted tooth; tooth rash; logistic models; retrospective studies.

Resumen: El objetivo del presente estudio fue evaluar si la protracción maxilar con mascarilla aumenta el riesgo de impactación canina maxilar. Materiales y método: se recogieron retrospectivamente los registros de 76 sujetos esqueléticos de Clase III con una etapa de maduración vertebral cervical entre CS1 y CS3 y un canino maxilar desplazado. Se recogieron fotografías intraorales, ortopantomografía y cefalogramas laterales, y los pacientes se dividieron en tres grupos según el tipo de tratamiento recibido: un expansor palatino rápido (RPE), un RPE junto con una máscara facial (RPE-FM) o un aparato funcional (FA) clase III. Los registros del paciente se usaron para determinar si los caninos maxilares entraron en erupción correctamente después de esa fase del tratamiento. Se utilizó una regresión logística binaria para evaluar el efecto de la modalidad de tratamiento y la etapa de maduración esquelética sobre la posibilidad de impactación canina maxilar. Resultados: no se observó ningún efecto de las tres modalidades de tratamiento diferentes y de la etapa de maduración esquelética sobre el riesgo de impactación canina. Conclusiones: la mascarilla de protracción se puede usar en sujetos esqueléticos clase III en crecimiento sin aumentar los riesgos de desplazamiento canino maxilar.

Palabras Clave: Ortodoncia correctiva; diente canino; diente impactado; erupción dental; modelos logísticos; estudios retrospectivos.

INTRODUCTION.

The impaction of maxillary canines is an eruption anomaly affecting about 2% of the population and is the most frequent impaction after that of mandibular and maxillary third molars.^{1,2} When the signs of an anomalous eruptive path of the maxillary canine are timely recognized, an interceptive treatment can be successful in a percentage of cases ranging from 65% up to 80%.^{3,4}

The early treatment of a palatally displaced canine involves the extraction of the deciduous canine⁵ and the transversal expansion of the palate with a rapid maxillary expander (RPE),^{3,4,6} possibly anchored on the deciduous second molars to reduce the risks associated with the RPE treatment.⁷⁻⁹ When the early treatment is unsuccessful or not feasible, the treatment of an impacted canine requires the surgical exposure and the orthodontic forced eruption of the tooth: this is a complex procedure for the clinician that requires an accurate surgical and biomechanical planning^{10,11} to apply physiologic forces in a convenient direction to reduce the risks of root resorption,¹²⁻¹⁴ a proper anchorage preparation, eventually with the use of miniscrews,¹⁵ and also for the patient that should expect a longer treatment time with respect to a treatment of a similar malocclusion without an impacted tooth.¹⁶ For these reasons, many authors studied techniques to prevent the impaction of the maxillary canines and efforts have been made to improve the methods to predict the risk of impaction. In addition to the assessment of the canine position on panoramic radiograph with the method proposed by Ericson *et al.*,¹⁷ some authors found that certain skeletal features, like a prognathic growth,¹⁸ a reduced sagittal and vertical dimension of the maxilla,¹⁹ and the facial divergence²⁰ can be used as predictor of maxillary canine impaction. All these characteristics are found in skeletal Class III subjects, and some studies confirmed this association,²¹ especially for maxillary canine-first premolar transposition,²² that is known to share a common genetic etiology with palatally displaced maxillary canines.²³

Therefore, it could be possible to observe young patients with a skeletal Class III and a maxillary canine with an altered eruptive path that need orthodontic treatment: some authors reported the occurrence of

maxillary canine impaction after a maxillary protraction with a facemask,^{24,25} that is one of the most common treatment modality for growing Class III patients.²⁶

The aim of the present study was to evaluate the effects of three treatment modalities –a REP, a REP combined with a facemask, and a Class III functional appliance– on the chance of eruption of displaced maxillary canines in Class III growing subjects. The null hypothesis was that there is no difference in the chance of eruption between the three treatment modalities.

MATERIALS AND METHODS.

The present manuscript was prepared following the STROBE guidelines. The records of the patients treated at the Department of Biotechnological and Applied Clinical Studies, University of L'Aquila, and at the Department of Experimental Medicine, University of Foggia, from January 2008 to June 2018 were screened for the following inclusion criteria:

- Pre-pubertal age at the start of treatment
- Class III malocclusion defined as an ANB angle $<0^\circ$ or a WITS appraisal $<-3\text{mm}$
- Orthodontic treatment with either a functional appliance, a REP, or a REP and a facemask
- A risk of maxillary canine impaction assessed on panoramic radiograph, showing an α -angle greater than 15° or a sector of impaction of S2 or worse, according to the criteria proposed by Ericson *et al.*¹⁷

The procedures were followed in accordance with the Helsinki Declaration of 1975, as revised in 2008, and were approved by the Internal Review Board of the University of L'Aquila. The records were retrieved retrospectively, were analysed anonymously, and patients and their legal tutors signed a written informed consent to participate in future research at the time that the records were taken.

Sample size calculation revealed that in order to be able to detect a medium effect size of 0.15 with a I-type error probability of 0.05 and a power of 0.8, 76 subjects were needed.

Pre-treatment intraoral photographs, orthopantomography, and lateral cephalograms of the selected subjects were collected, then information about early-treatment intervention were retrieved from patients' histories.

Intraoral photographs and orthopantomography taken after this stage of treatment were also collected. The pre-treatment lateral cephalograms were used to determine the skeletal maturation stage according to the Cervical Vertebral Maturation (CVM) method by a single operator (MT).²⁷ To evaluate the reliability of the CVM assessment,³⁰ randomly selected lateral cephalograms were reassessed by the same operator at a 1-week interval, and intra-operator agreement was calculated using Cohen's weighted kappa.

Depending on the type of intervention, if patients received a Rapid Palatal Expander (RPE), a RPE together with a protraction facemask (RPE-FM), or a functional appliance like Frankel-III or S.O.C.I.A.²⁸ (FA), patients were included in the RPE group, in the RPE-FM group, or in the FA group. The RPE appliance used was a Hyrax expander with two bands for the upper first molars. Post-treatment records were used to determine if the maxillary canines that showed a risk of impaction at treatment start, were erupted correctly or showed a palatal or buccal displacement. Those patients with ectopic canines at the end of treatment, were classified as 'impacted'.

Statistical analysis

Frequencies and distribution were calculated for

erupted or impacted canines among the three groups. A binary logistic regression was computed to evaluate the effect of each treatment modality –RPE, RPE-FM, or FA– and CVM stage on the probability of having an erupted or impacted canine at the end of treatment. The first type error was set as $p < 0.05$.

RESULTS.

The records of 76 patients (36 males, 40 females) were selected from the 300 initially screened, according to the inclusion criteria and according to sample size calculation. All the included subjects showed a skeletal maturation stage between CS1 and CS3 (Table 1), according to the CVM method,²⁷ with a mean age of 9.9 ± 2.6 years. Intra-operator agreement for CVM evaluation as calculated with Cohen's kappa with square weights was 99.4% ($\text{kappa} = 0.95$; $p < 0.001$).

Frequencies of erupted or impacted canines in the three treatment groups are reported in Table 1. The binary logistic regression was able to correctly predict only 56.5% of the cases, showing a very low fitting. No statistically significant effect of treatment modality and CVM stage on the probability of having an erupted or impacted canine was observed (Table 2), therefore the null hypothesis was accepted.

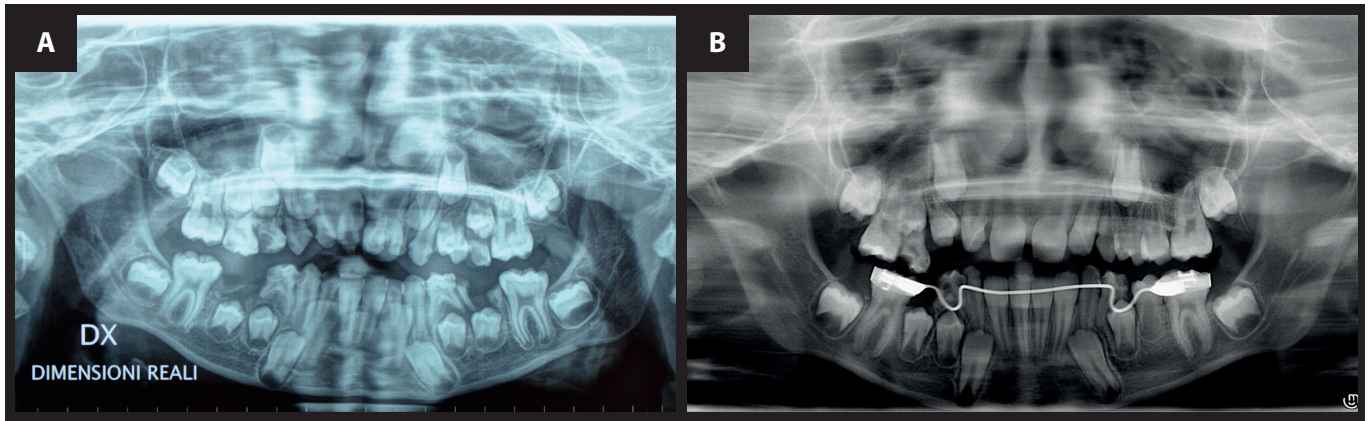
Table 1. Demographic composition of the sample and distribution of treatment modalities and canine impaction.

Maxillary canines	CVM		RPE	RPE and Facemask	Functional appliance	Total
	CS1-CS2	CS3				
Erupted	24	10	9	12	13	34
Impacted	25	17	8	16	18	42
Total	49	27	17	28	31	76

Table 2. Binary logistic regression for the effect of appliance on the risk of maxillary canine impaction (n= 76).

	B	S.E.	Wald	df	p-value	Exp(B)	95% Confidence interval for Exp(B)	
							Lower	Upper
RPE and Facemask	0.06	0.54	0.01	1	0.905	1.07	0.37	3.09
RPE	-0.29	0.63	0.76	1	0.640	0.74	0.21	2.57
CVM stage	0.45	0.51	0.76	1	0.383	1.56	0.57	4.27
Constant	0.32	0.36	0.80	1	0.371	1.40		

Figure 1. Orthopantomography of a patient that received an interceptive treatment with Rapid Palatal Expansion and Facemask.



A: Pre-treatment orthopantomography. **B:** Orthopantomography after facemask, showing the upper left maxillary canine retained over the root of the first premolar.

DISCUSSION.

The aetiology of maxillary impacted canines is still a debated argument. It is accepted that buccally displaced and palatally displaced maxillary canines are different entities: the buccal impaction of a maxillary canine is primarily caused by a space deficiency in the arch, while the palatal displacement of a maxillary canine is attributed either to local or genetic factors.²⁹

Local factors that can cause the displacement of the canine include odontomas, supernumerary teeth, hard-tissue pathologies, trauma and root dilacerations, cysts and granulomas, and anomalies of the lateral incisors.

In particular, anomalies of the lateral incisors like microdontia, peg-shaped laterals or tooth agenesis are strongly associated with palatally displaced maxillary canines:³⁰ this observation is the basis for the so-called guidance-theory of the aetiology of palatally displaced canines.

As described by Broadbent in 1941,³¹ the tooth buds of the maxillary canines originate in a high position in the maxillary bone, with a mesial and palatal inclination; as the root continues to develop, the tooth moves occlusally until it reaches the root of the lateral incisors. At this point, the canine changes its inclination to distal and buccal, then reaching its final position in the arch.

The role of the root of the lateral incisor during this process is considered fundamental, and any anomaly

that can alter the guidance role of the lateral incisor can cause an impaction.³⁰ Other authors assign a preeminent role to genetic factors: the genetic theory is based on the association of maxillary impacted canines with other anomalies with a genetic cause like tooth agenesis and tooth transposition, the observation of bilateral occurrence of impacted canines, gender and ethnicity differences in prevalence of impacted canines, and familial occurrence.²⁹

Moreover, some authors studied other factors that could be used to predict the risk of canine impaction, such as skeletal features.²⁰ Mercuri *et al.*,¹⁸ reported that patients with impacted canines were characterised by a horizontal and prognathic growth and Larsen *et al.*,¹⁹ found that the dimension of the maxilla in subjects with palatally displaced canines was reduced vertically and sagittally, but increased transversally.

However, no clear correlation between a Class III skeletal pattern and the impaction of maxillary canines has been demonstrated. Di Carlo *et al.*,³² evaluated the prevalence of maxillary canine impaction in Class III patients compared to Class I subjects, and found no significant differences. Nevertheless, Basdra *et al.*,²¹ observed the displacement of maxillary canines in 9% of skeletal Class III patients.

The gold-standard treatment modality for growing skeletal Class III subjects is the maxillary protraction with facemask, as widely supported by many studies,²⁶

therefore a number of Class III subjects with a risk of canine impaction could receive a protraction facemask as a treatment modality. Some case reports in the literature reported maxillary canines that were impacted after Class III treatment with facemask,²⁴ and this has been also anecdotally claimed by some authors.

It is reported that one of the treatment modalities for ectopic erupting canines is to increase the space in the arch in the canine area,⁴ therefore it is plausible that, conversely, a loss of arch space could prevent a correct eruption of the maxillary canines.

In fact, while buccally displaced canines are strongly associated with dental crowding but palatally displaced canines are associated with dental spacing, a loss of space in the canine area –for example due to a mesiorotation of the first premolar– can also cause a maxillary canine to become impacted.³⁰

Such space loss can be a side-effect of the facemask, that is known to be possibly accompanied by dental anchorage loss and mesial movement of the maxillary molars (Figure 1), and that these effects increase with patient's age.³³

However, the findings of the present study denied such hypothesis, since no effect of treatment modality on the chance of canine eruption was observed (Table 2). The RPE group showed a similar rate of erupted/impacted canines, while the REP-FM group and the FA group presented a greater number of impacted canines compared to the erupted canines (Table 1), however, these numbers did not reach statistical significance. In addition, no effect of pre-treatment CVM stage was observed. Therefore, maxillary protraction with

facemask can be administered even to patients with displaced maxillary canines, without increasing the risk of canine impaction.

One of the limitations of the present study is its retrospective design, although care was taken to reduce any possible source of bias during the patient selection procedure, following a chronological order and using an a priori sample size calculation.

CONCLUSION.

The present study revealed no effect of treatment modality nor CVM stage on the chance of canine eruption. Maxillary protraction with facemask does not increase the risk of impaction of maxillary canines.

Conflict of interests: The authors declare no conflict of interest of any kind.

Ethics approval: The present research protocol was approved by the Internal Review Board of the University of L'Aquila, reference No 1961.

Funding: Self-funded

Author's contribution: Michele Tepedino: Drafted the manuscript and performed the statistical analysis. Graziano Montaruli: screened the records and acquired the data. Maciej Iancu Potrubacz: performed the literature search and acquired the data. Letizia Perillo: interpreted the data and revised the paper. Claudio Chimenti: interpreted the data and revised the paper. Domenico Ciavarella: Supervised the work and revised the paper.

Acknowledgements: None.

REFERENCES.

1. Ericson S, Kurol J. Early treatment of palatally erupting maxillary canines by extraction of the primary canines. *Eur J Orthod.* 1988;10(4):283-295.
2. Luzzi V, Ierardo G, Corridore D, Di Carlo GI, Di Giorgio G, Leonardi E, Campus GG, Voza I, Polimeni A, Bossù M. Evaluation of the orthodontic treatment need in a paediatric sample from Southern Italy and its importance among paediatricians for improving oral health in pediatric dentistry. *J Clin Exp Dent.* 2017;9(8):e995-e1001.
3. Baccetti T, Mucedero M, Leonardi M, Cozza P. Interceptive treatment of palatal impaction of maxillary canines with rapid maxillary expansion: a randomized clinical trial. *Am J Orthod*

Dentofac Orthop. 2009;136(5):657-661.

4. Sigler LM, Baccetti T, McNamara JA. Effect of rapid maxillary expansion and transpalatal arch treatment associated with deciduous canine extraction on the eruption of palatally displaced canines: A 2-center prospective study. *Am J Orthod Dentofac Orthop.* 2011;139(3):e235-e244.

5. Naoumova J, Kurol J, Kjellberg H. Extraction of the deciduous canine as an interceptive treatment in children with palatal displaced canines - part I: Shall we extract the deciduous canine or not? *Eur J Orthod.* 2015;37(2):209-218.

6. Staderini E, Patini R, De Luca M, Gallenzi P. Three-dimensional stereophotogrammetric analysis of nasolabial soft

- tissue effects of rapid maxillary expansion: a systematic review of clinical trials. *Acta Otorhinolaryngol Ital.* 2018;38(5):399-408.
7. Mutinelli S, Cozzani M. Rapid maxillary expansion in early-mixed dentition: effectiveness of increasing arch dimension with anchorage on deciduous teeth. *Eur J Paediatr Dent.* 2015;16(2):115-122.
 8. Tepedino M, Iancu-Potrubacz M, Ciavarella D, Masedu F, Marchione L, Chimenti C. Expansion of permanent first molars with rapid maxillary expansion appliance anchored on primary second molars. *J Clin Exp Dent.* 2018;10(3):e241-e247.
 9. Monaco A, Tepedino M, Sabetti L, Petrucci A, Sgolastra F. An adolescent treated with rapid maxillary expansion presenting with strabismus: A case report. *J Med Case Rep.* 2013;7:222.
 10. Becker A, Chaushu S. Success rate and duration of orthodontic treatment for adult patients with palatally impacted maxillary canines. *Am J Orthod Dentofac Orthop.* 2003;124(5):509-14.
 11. Bishara SE. Impacted maxillary canines : A review. *Am J Orthod Dentofac Orthop.* 1992;101(2):159-71.
 12. Tepedino M, Chimenti C, Masedu F, Iancu Potrubacz M. Predictable method to deliver physiologic force for extrusion of palatally impacted maxillary canines. *Am J Orthod Dentofac Orthop.* 2018;153(2):195-203.
 13. Iancu Potrubacz M, Chimenti C, Marchione L, Tepedino M. Retrospective evaluation of treatment time and efficiency of a predictable cantilever system for orthodontic extrusion of impacted maxillary canines. *Am J Orthod Dentofac Orthop.* 2018;154(1):55-64.
 14. Staderini E, Guglielmi F, Cornelis MA, Cattaneo PM. Three-dimensional prediction of roots position through cone-beam computed tomography scans-digital model superimposition: A novel method. *Orthod Craniofac Res.* 2019;22(1):16-23.
 15. Tepedino M, Masedu F, Chimenti C. Comparative evaluation of insertion torque and mechanical stability for self-tapping and self-drilling orthodontic miniscrews - An in vitro study. *Head Face Med.* 2017;13(10):1-7.
 16. Stewart JA, Heo G, Glover KE, Williamson PC, Lam EW M, Major PW. Factors that relate to treatment duration for patients with palatally impacted maxillary canines. *Am J Orthod Dentofac Orthop.* 2001;119(3):216-25.
 17. Ericson S, Kurol J. Radiographic Examination of Ectopically Erupting Maxillary Canines. *Am J Orthod Dentofac Orthop.* 1987;91(6):483-92.
 18. Mercuri E, Cassetta M, Cavallini C, Vicari D, Leonardi R, Barbato E. Skeletal features in patient affected by maxillary canine impaction. *Med Oral Patol Oral Cir Bucal.* 2013;18(4):e597-602.
 19. Larsen H, Sorensen H, Artmann L, Christensen I, Kjaer I. Sagittal, vertical and transversal dimensions of the maxillary complex in patients with ectopic maxillary canines. *Orthod Craniofac Res.* 2010;13(9):34-9.
 20. Laurenziello M, Montaruli G, Gallo C, et al. Determinants of maxillary canine impaction: Retrospective clinical and radiographic study. *J Clin Exp Dent.* 2017;9(11):e1304-e1309.
 21. Basdra EK, Kiokpasoglou MN, Komposch G. Congenital tooth anomalies and malocclusions: A genetic link? *Eur J Orthod.* 2001;23(2):145-51.
 22. Danielsen JC, Karimian K, Ciarlantini R, Melsen B, Kjær I. Unilateral and bilateral dental transpositions in the maxilla—dental and skeletal findings in 63 individuals. *Eur Arch Paediatr Dent.* 2015;16(6):467-76.
 23. Scerri ES, McDonald F, Camilleri S. Comparison of the dental anomalies found in maxillary canine-first premolar transposition cases with those in palatally displaced canine cases. *Eur J Orthod.* 2016;38(1):79-84.
 24. Oz AZ, Taner T. Displacement of maxillary canines after facemask treatment: a case report. *Int J Orthod Milwaukee.* 2014;25(2):47-9.
 25. Iancu Potrubacz M, Tepedino M, Chimenti C. Maxillary canine–first premolar bilateral transposition in a Class III patient: A case report. *Angle Orthod.* 2015.
 26. Ngan P, Moon W. Evolution of Class III treatment in orthodontics. *Am J Orthod Dentofac Orthop.* 2015;148(1):22-36.
 27. Baccetti T, Franchi L, McNamara J A. The Cervical Vertebral Maturation (CVM) Method for the Assessment of Optimal Treatment Timing in Dentofacial Orthopedics. *Semin Orthod.* 2005;11(3):119-29.
 28. Ciavarella D, Mastrovincenzo M, Tepedino M, et al. Early treatment of pseudo-class III malocclusion with modified swallowing occlusal contact intercept appliance (S.O.C.I.A.). *J Indian Soc Pedod Prev Dent.* 2018;36(2):206-12.
 29. Peck S, Peck L, Kataja M. The palatally displaced canine as a dental anomaly of genetic origin. *Angle Orthod.* 1994;64(4):249-56.
 30. Becker A, Chaushu S. Etiology of maxillary canine impaction: A review. *Am J Orthod Dentofac Orthop.* 2015;148(4):557-67.
 31. Broadbent BH. Ontogenic Development of Occlusion. *Angle Orthod.* 1941;11(4):223-41.
 32. Di Carlo G, Saccucci M, Luzzi V, et al. Prevalence of maxillary canine impaction in skeletal Class III malocclusions compared to Class I malocclusions. *J Clin Exp Dent.* 2019;11(3):e264-8.
 33. Clemente R, Contardo L, Greco C, Di Lenarda R, Perinetti G. Class III Treatment with Skeletal and Dental Anchorage: A Review of Comparative Effects. *Biomed Res Int.* 2018;2018:1-10.