

Pierre Robin Sequence: airway management via mandibular distraction. Case report.

Secuencia de Pierre Robin: manejo de vía aérea mediante distracción ósea mandibular. Reporte de caso.

Hernán Arango Fernández.¹
Martha Rebolledo Cobos.²
Saulo Pineda Ovalle.¹
Jonathan Harris Ricardo.³

Affiliations: ¹Servicio de Cirugía Oral y Maxilofacial, Fundación Hospital Universitario Metropolitano. Barranquilla, Colombia. ²Departamento de Cirugía Oral, Universidad Metropolitana. Laboratorio de Genética Molecular, Universidad Simón Bolívar. Barranquilla, Colombia. ³Departamento de Medicina Oral, Clínica Odontológica de la Corporación Universitaria Rafael Núñez. Cartagena, Colombia.

Corresponding author: Jonathan Harris Ricardo. Departamento de Medicina Oral, Clínica Odontológica de la Corporación Universitaria Rafael Núñez. Cartagena, Colombia. Email: j.harris.r@hotmail.com

Receipt: 11/08/2018 **Revised:** 12/03/2018
Acceptance: 01/07/2019 **Online:** 08/05/2019

Cite as:

Arango Fernández H, Rebolledo Cobos M, Pineda Ovalle S, Harris Ricardo J. Pierre Robin Sequence: airway management via mandibular distraction. Case report. J Oral Res 2019; 8(3):244-248. DOI: 10.17126/joralres.2019.036.

Abstract: Pierre Robin sequence is a set of congenital conditions characterized by the presence of micrognathia, glossoptosis, cleft palate and obstruction of the airways. The latter can lead to many other complications such as respiratory difficulties, apnea, weight loss and even death. Currently, mandibular distraction, or the lengthening of the mandibular bone, is the most common surgical procedure used to correct a retracted tongue and the airway obstruction it produces in patients with mandibular hypoplasia. The present paper reports the case of a 26-day-old male patient, who presented obstruction on the upper respiratory tract, mandibular retromicrognathia, and retracted tongue and cleft palate, all conditions characteristic to Pierre Robin sequence. The patient also had a medical record of orotracheal intubation due to respiratory difficulties. The subject underwent mandibular distraction surgery with a horizontal vector, which resulted in a satisfactorily cleared airway.

Keywords: Osteogenesis; distraction; micrognathia; Pierre Robin Syndrome; airway obstruction.

Resumen: La secuencia de Pierre Robin es una afección congénita caracterizada por la presencia de micrognatia, glosoptosis, paladar hendido y obstrucción de la vía aérea, siendo ésta una de las principales características de la cual derivan varias complicaciones, entre ellas, dificultad respiratoria, apnea, pérdida de peso y hasta la muerte. En la actualidad la distracción ósea mandibular es la técnica quirúrgica de elección, que tiene como finalidad el alargamiento mandibular corrigiendo la posición posterior de la lengua, con la consecuente desobstrucción de la vía aérea en pacientes con hipoplasia mandibular. Se reporta caso clínico de paciente masculino con 26 días de nacido, que presentó obstrucción de la vía aérea superior, retromicrognatismo mandibular, retracción de la lengua y hendidura palatina, relacionado con la secuencia de Pierre Robin, con antecedentes de intubación orotraqueal por dificultad respiratoria, al cual se le realizó distracción ósea mandibular con vector horizontal, destacando resultados satisfactorios en la resolución de la obstrucción de la vía aérea.

Palabras Clave: Osteogénesis por distracción; micrognatismo; Síndrome de Pierre Robin; obstrucción de las vías aéreas.

INTRODUCTION.

Pierre Robin Sequence (PRS) is a chain of conditions that stem from the improper development of the mandible, with micrognathia causing the misplacement of the tongue into the back of the mouth. The tongue might interfere with the development of the palatal shelves, resulting in a U-shape cleft palate. The accompanying reduction of the oropharyngeal airways leads to upper respiratory tract obstruction (URTO), and patients may present

obstructive sleep apnea symptoms that may require tracheostomy surgery in extreme cases.^{1,2}

Treatment may greatly vary depending on the severity of the URTO. Some affected newborns can be treated without surgery using a palate obturator in order to clear the blocked airways. Daniel *et al.*,⁴ reported good results using long term nasopharyngeal intubation treatment or continuous positive airway pressure treatment. Surgery is commonly reserved for more severe cases. While it is true that a tracheotomy clears URTO, it is associated with a high mortality rate, and it does not correct the underlying anatomic abnormality that causes the problem. A proper mandibular development is key for clearance at the base of the tongue in order to prevent subsequent URTOs.³⁻⁵

Distraction osteogenesis is a de novo biological bone formation process where traction pressure is applied.

It begins with a corticotomy that weakens the bone, followed by the implantation and activation of a distractor that generates the progressive separation of the fracture and immobilizes fragments, resulting in the lengthening of the mandibular bone and the simultaneous growth of muscle and soft tissue. It is important to preserve vascularization, and to provide adequate post-operative and distraction period.⁶

Mandibular distraction osteogenesis (MDO) corrects micrognathia, gradually lengthens the mandible, and can be performed safely in infants. This procedure successfully prevents obstructive sleep apnea in most cases, thus avoiding the need for tracheotomy surgery.^{7,8}

The aim of the present study is to report the positive results of MDO in the treatment of URTO on a newborn afflicted with PRS.

Figure 1. Mandibular micrognathia in a twenty-six-day old infant.

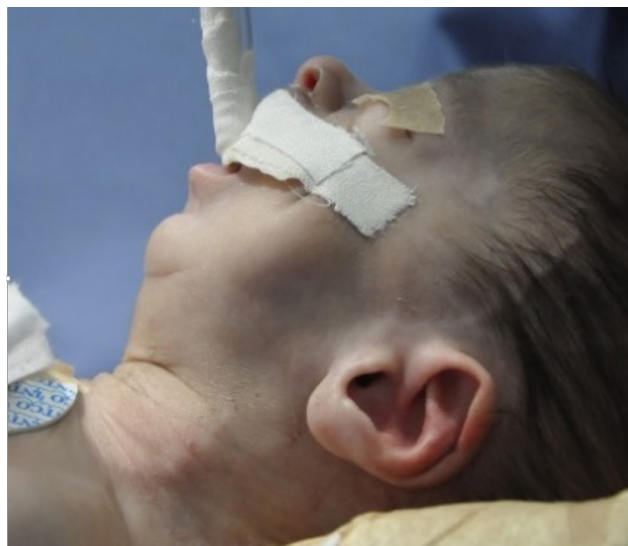

Figure 2. Neck computed tomography of a twenty-six-day old infant; a decrease in airway size is apparent.

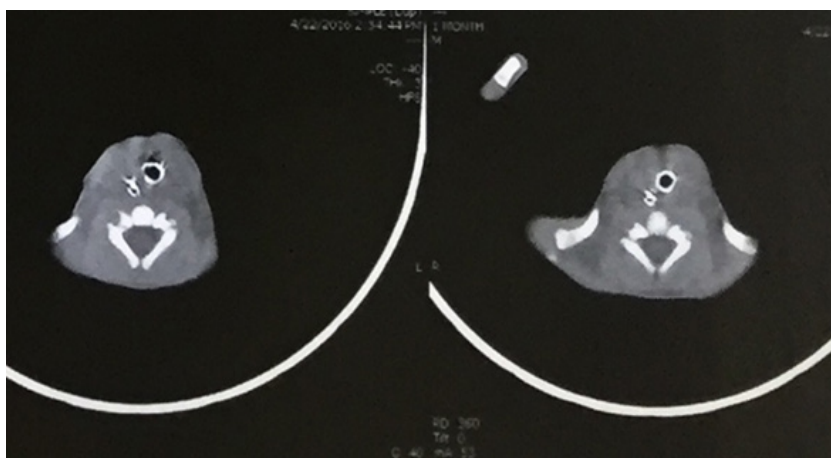
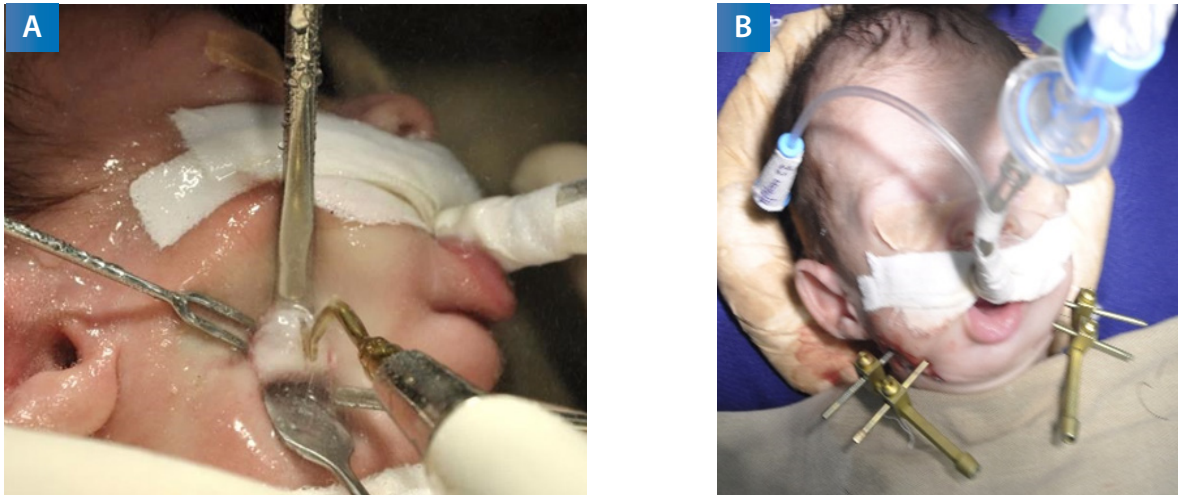
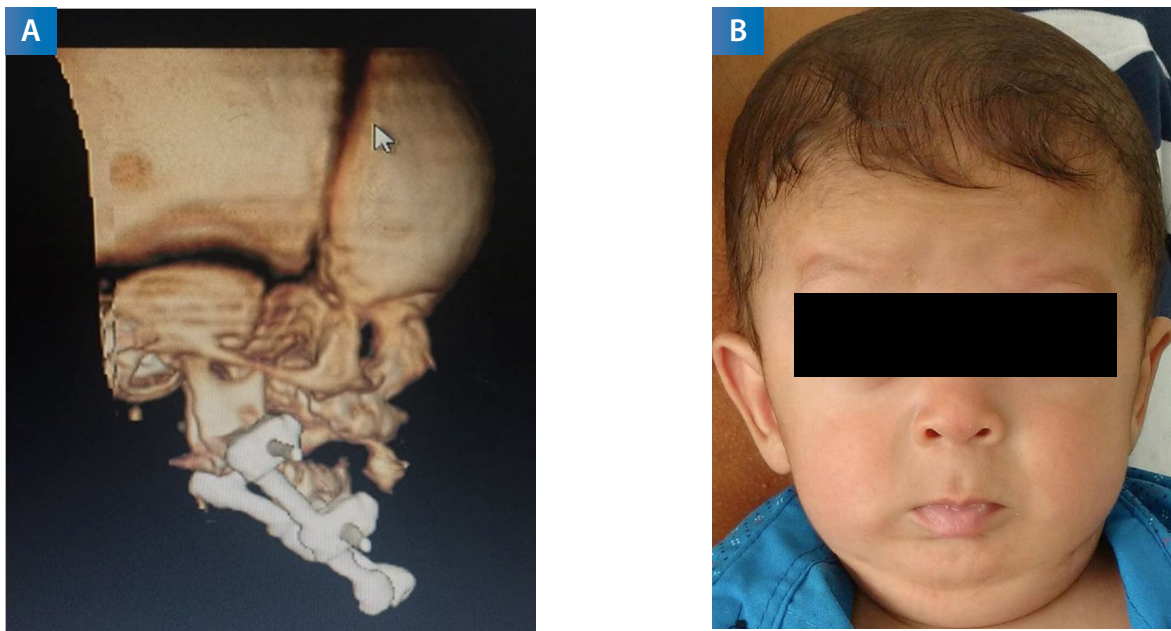


Figure 3. Mandibular osteotomy.



A: Mandibular osteotomy on the right side. **B:** Bilateral mandibular distraction device.

Figure 4. Post-operative tridimensional reconstruction.



A: Post-operative tridimensional reconstruction. **B:** Clinical control at 5 months post-surgery. No respiratory difficulties and better maxillomandibular skeletal relationship.

CASE

A male twenty-six-day old infant was admitted into the oral and maxillofacial surgery department of the Fundación Hospital Universitario Metropolitano in Barranquilla, Colombia. The patient suffered from PRS-related URTO, was a premature baby, presented low birthweight and a medical record of mitral valve regurgitation, bronchopulmonary dysplasia, cryptorchidism of the right testicle, and had undergone

oro-tracheal intubation due to respiratory difficulties.

The patient was evaluated by a specialist multi-disciplinary team that recommended a tracheotomy in order to handle the airways, and a gastrostomy for feeding. During physical examination it was observed that the patient presented mandibular retromicrognathia, a convex facial profile Figure 1, type II skeletal maxillary-mandibular relationship, tongue retraction and a U-shaped cleft palate.

A significant decrease in the size of the airways was also observed in the axial cut of a neck computed tomography (CT), Figure 2.

Taking into consideration the medical history as well as the clinical scenario at the time, a bilateral MDO was proposed, comprising the insertion of an extra oral unidirectional screw-type distraction device with a horizontal distraction vector, as well as a palatorrhaphy at the time of a second surgical intervention. The mandibular distraction protocol included a 3-day-latency period followed by 1mm of daily activation of the device, or 0.5mm every 12 hours. The patient's guardian provided signed informed consent, where the risks and benefits of the treatment were stipulated. The surgery was performed under general anesthesia, after a pre-anesthetic evaluation.

Subsequently, an orotracheal intubation was performed without complication. The procedure began with a submandibular incision on the right side, 1cm below the mandibular border, followed by a dissection by planes until reaching the mandibular angle. A corticotomy was performed on the external face of the mandibular angle Figure 3A, and the distractor device was inserted.

The procedure was repeated on the other side (left), resulting in the insertion of bilateral distractor devices Figure 3B.

Hemostasis and suture of the planes was then performed. The procedure ended without complications, and the patient was admitted to the neonatal intensive care unit. The distraction protocol was executed for 6 weeks, resulting in 23mm of mandibular distraction.

A follow-up CT scan and a tridimensional reconstruction side view presented a larger diameter on the airway and other distracted segments Figure 4A.

After 6 weeks of fracture healing, the estimated time for proper bone regeneration, the device was removed under anesthetic sedation.

The patient was controlled monthly, and positive results regarding the airways and the maxillomandibular skeletal relationship were observed after 5 months post-surgery Figure 4B.

During physical examination, the patient presented adequate respiratory capacity, deglutition, nutrition, and overall good health, resulting in a better quality of life.

DISCUSSION.

PRS is a congenital affliction characterized by micrognathia, glosptosis and other various effects on the stability of the airways. Newborn babies present respiratory difficulties, which manifest through stridor and oxygen desaturation, as well as eating and developmental problems. The treatment for URTO in babies with PRS can be divided in two groups: surgical procedures and nonsurgical techniques. Among the surgical procedures, the most common are tracheotomy, release of the floor of the mouth, and MDO, with the latter presenting excellent results. Li *et al.*,¹⁰ stated that non-surgical techniques do not correct anatomical problems, and that surgical procedures are determined by the the clinical characteristics and imaging studies of each case.⁹

Resnick *et al.*,¹¹ have emphasized the role of new computer imaging technologies during the planning and process of surgery. The use of such tools, like tridimensional images, results in higher success rates while reducing complications during surgical procedures.

Regarding MDO as a URTO treatment in patients with PRS-related micrognathia, Hong et al. carried out a study on 16 affected children. Its results showed that the procedure can be safely and effectively performed on newborn babies with severe micrognathia and URTO. Breik et al. reported in a literature review that MDO successfully prevents the need for tracheostomy in 95% of the cases. Sesenna *et al.*,¹⁴ presented a series of nine cases of PRS with severe micrognathia and URTO where 100% responded favorably to bilateral MDO procedures, with the complete resolution of respiratory symptoms. These results coincide with the present case, of a patient afflicted with airway obstruction and who was treated with MDO surgery. Positive results were observed after 6 weeks of treatment without any alterations in breathing or deglutition, and a considerable improvement in the skeletal maxillomandibular relationship.¹²

Martínez *et al.*,¹⁵ state that the use of a horizontal vector is key for airway enlargement at the retropharyngeal space, and mandibular distraction treatment of retromicrognathia. Use of MDO in the long term may result in anomalies such as mild cases of anterior open bite that can be corrected spontaneously or through the use of orthodontic devices.

CONCLUSION.

PRS treatment usually requires the participation of multidisciplinary teams.

Horizontal vector MDO is the proper surgical technique for the treatment of URTO secondary to PRS since it corrects anatomical defects, and in a few days can modify eating alterations and aid in oxygen saturation.

REFERENCES.

1. Insalaco LF, Scott AR. Peripartum Management of Neonatal Pierre Robin Sequence. *Clin Perinatol*. 2018;45(4):717-35.
2. Côté A, Fanous A, Almajed A, Lacroix Y. Pierre Robin sequence: review of diagnostic and treatment challenges. *Int J Pediatr Otorhinolaryngol*. 2015;79(4):451-64.
3. Bütow KW, Morkel JA, Naidoo S, Zwahlen RA. Pierre Robin sequence: Subdivision, data, theories, and treatment - Part 2: Syndromic and nonsyndromic Pierre Robin sequence. *Ann Maxillofac Surg*. 2016;6(1):35-7.
4. Daniel M, Bailey S, Walker K, Hensley R, Kol-Castro C, Badawi N, Cheng A, Waters K. Airway, feeding and growth in infants with Robin sequence and sleep apnoea. *Int J Pediatr Otorhinolaryngol*. 2013;77(4):499-503.
5. Greathouse ST, Costa M, Ferrera A, Tahiri Y, Tholpady SS, Havlik RJ, Flores RL. The Surgical Treatment of Robin Sequence. *Ann Plast Surg*. 2016;77(4):413-9.
6. Martín-Masota R, Osorio-Cámara JM, Martínez-Plaza A, Ocete-Hita E. Distracción mandibular ósea: resultados del postoperatorio inmediato. *Rev Esp Cir Oral Maxilofac*. 2018;40(1):1-6.
7. Ching JA, Daggett JD, Alvarez SA, Conley CL, Ruas EJ. A Simple Mandibular Distraction Protocol to Avoid Tracheostomy in Patients With Pierre Robin Sequence. *Cleft Palate Craniofac J*. 2017;54(2):210-5.
8. Couce ML, Baña A, Pérez-Muñuzuri A, Albertos-Castro J, García-Rielo JM, Fraga JM. [Usefulness of mandibular distraction in the Pierre Robin sequence in neonates]. *An Pediatr*. 2014;80(2):e42-3.
9. Lee JC, Bradley JP. Surgical considerations in pierre robin sequence. *Clin Plast Surg*. 2014;41(2):211-7.
10. Li WY, Poon A, Courtemanche D, Verchere C, Robertson S, Bucevska M, Malic C, Arneja JS. Airway Management in Pierre Robin Sequence: The Vancouver Classification. *Plast Surg*. 2017 Feb;25(1):14-20.
11. Resnick CM. Precise osteotomies for mandibular distraction in infants with Robin sequence using virtual surgical planning. *Int J Oral Maxillofac Surg*. 2018;47(1):35-43.
12. Hong P, Kearns D. Airway characteristics of infants with Pierre Robin sequence who undergo mandibular distraction osteogenesis. *Ear Nose Throat J*. 2015;94(8):E25-9.
13. Breik O, Tivey D, Umapathysivam K, Anderson P. Mandibular distraction osteogenesis for the management of upper airway obstruction in children with micrognathia: a systematic review. *Int J Oral Maxillofac Surg*. 2016;45(6):769-82.
14. Sesenna E, Magri AS, Magnani C, Brevi BC, Anghinoni ML. Mandibular distraction in neonates: indications, technique, results. *Ital J Pediatr*. 2012;38:7.
15. Martínez-Plaza A, Fernández-Valadés R, España-López A, García-Medina B, Capitán Cañadas LM, Monsalve-Iglesias F. Cambios en la dimensión de la vía aérea en pacientes con secuencia de Pierre-Robin asociada a síndromes malformativos tras distracción mandibular: planificación del vector de distracción. *Rev Esp Cirug Oral y Maxilofac*. 2015, 37(2):71-9.

Conflict of interests: There is no conflict of interest among the authors.

Ethics approval: None.

Funding: There is no funding for the study.

Authors' contributions: Hernán Arango Fernández and Saulo Pineda Ovalle: They performed the surgical procedure. Martha Rebolledo Cobos: I performed the surgical procedure and the preparation of the manuscript. Jonathan Harris Ricardo: I made the manuscript preparation.

Acknowledgements: None.