

## Relationship between cervical vertebral maturation and dental development in a sample of yemeni children and adolescents.

Relación entre la maduración vertebral cervical y el desarrollo dental en una muestra de niños y adolescentes Yemeníes.

Ali Al-Aunhomi.<sup>1</sup>  
Khalid Aldhorae.<sup>2</sup>  
Ramy Ishaq.<sup>1</sup>  
Mohammed Al-Labani.<sup>1</sup>  
Sadeq Al-Maweri.<sup>3</sup>  
Amin Al-Ashtal.<sup>1</sup>

### Affiliations:

<sup>1</sup>Department of orthodontics, Faculty of Dentistry, university of Science and Technology, Sana, Yemen.

<sup>2</sup>Head of orthodontic Department, college of dentistry, University of Thamar, Thamar, Yemen.

<sup>3</sup>Department of Oral Medicine and Diagnostic Sciences, Al-Farabi Colleges, Riyadh, Saudi Arabia.

**Corresponding author:** Khalid Aldhorae. Head of orthodontic Dept, college of dentistry, University of Thamar, Thamar, Yemen. **E-mail:** drdurai2008@gmail.com

**Receipt** : 04/24/2018 **Revised** : 08/14/2018  
**Acceptance** : 08/16/2019

### Cite as:

Al-Aunhomi A, Aldhorae K, Ishaq R, Al-Labani M, Al-Maweri S, Al-Ashtal A.

Relationship between cervical vertebral maturation and dental development in a sample of yemeni children and adolescents.

J Oral Res 2020; 9(1):7-13.

**Doi:**10.17126/joralres.2020.002

**Abstract:** Objective: This study was conducted to investigate the relationship between dental development and cervical vertebral maturation stages in a group of Yemeni children and adolescents. **Materials and Methods:** The study included digital panoramic radiographs and lateral skull cephalograms obtained from 207 Yemeni subjects—122 females and 85 males aged between 8 to 18 years. Dental maturity was evaluated according to the method of Demirjian *et al.*,<sup>6</sup> calcification stages of the left mandibular canines, first and second premolars and second molars were assessed. Skeletal maturity was assessed by the cervical vertebral maturation (CVM) stages according to the method of Baccetti *et al.*<sup>10</sup> Correlation between CVM and dental maturation was evaluated by Spearman rank-order correlation coefficient (SROCC). **Results:** CVM and dental calcification stages were highly correlated ( $p < 0.001$ ) in both genders, ranging from 0.686 to 0.873 for females and 0.787 to 0.871 for males. Calcification stages of the second molars showed the strongest correlation with CVM. **Conclusion:** Calcification stages of the second molar may be used as a reliable maturation indicator. Dental maturation may be applied to determine the skeletal maturity status of Yemeni children and adolescents.

**Keywords:** Cervical Vertebral Maturation; Dental development; Baccetti method; Demirjian, s method; Orthodontics; Calcification.

**Resumen:** Objetivo: Este estudio se realizó para investigar la relación entre el desarrollo dental y las etapas de maduración vertebral cervical en un grupo de niños y adolescentes yemeníes. **Material y Métodos:** El estudio incluyó radiografías panorámicas digitales y cefalogramas laterales del cráneo obtenidos de 207 sujetos yemeníes: 122 mujeres y 85 hombres de entre 8 y 18 años. La madurez dental se evaluó de acuerdo con el método de Demirjian *et al.*<sup>6</sup> Se evaluaron las etapas de calcificación de los caninos mandibulares izquierdos, primer y segundo premolares y segundos molares. La madurez esquelética se evaluó mediante las etapas de maduración vertebral cervical (CVM) de acuerdo con el método de Baccetti *et al.*<sup>10</sup> La correlación entre la CVM y la maduración dental se evaluó mediante el coeficiente de correlación de orden de rango de Spearman (SROCC). **Resultado:** Las etapas de CVM y calcificación dental estuvieron altamente correlacionadas ( $p < 0.001$ ) en ambos sexos, con un rango de 0.686 a 0.873 para las mujeres y 0.787 a 0.871 para los hombres. Las etapas de calcificación de los segundos molares mostraron la correlación más fuerte con CVM. **Conclusión:** las etapas de calcificación del segundo molar pueden usarse como un indicador de maduración confiable. La maduración dental puede aplicarse para determinar el estado de madurez esquelética de los niños y adolescentes yemeníes.

**Palabra Clave:** Maduración vertebral, Desarrollo Dental, Método Baccetti, Método Demirjian, Ortodoncia, Calsificación.

## INTRODUCTION.

The orthodontic treatment of growing patients is influenced by factors that include craniofacial growth. Diagnosis, treatment planning and treatment strategies may differ for patients who are still growing.

The growth pattern may play a role in the etiology of malocclusion.<sup>1</sup> The maturational status and the timing of pubertal growth spurt influence the timing, prognosis and success of functional orthopedics.<sup>12-13</sup> The most effective orthodontic treatment using functional appliances happens when it coincides with adolescent growth spurt peak.<sup>14,16-23</sup> The importance of growth assessment for orthodontic patients is the driving force for the quest for a reliable maturity indicator.

Chronological age cannot be relied upon due to the variability between individuals. This has led to the concept of biological or physiological age. The currently applied indicators include skeletal maturation, dental maturation, secondary sexual characteristics and body height changes. These indicators are used to evaluate the amount of remaining growth and to predict the timing of pubertal growth spurt.<sup>2</sup>

Skeletal maturation is assessed by radiographic appearance of hand and wrist bones or the cervical vertebrae. Cervical vertebrae (CV) are reliable indicators of skeletal maturity.<sup>4</sup> Recently, the assessment of cervical vertebrae utilizing lateral Cephalometric radiographs has become the preferable method for evaluating growth. Such method is currently widely used by orthodontists in order to reduce the need for an extra dose of radiation to which the patient is exposed.<sup>3-5</sup> This method, however, has its limitations. According to Nestman *et al.*,<sup>26</sup> CVM is a method with poor reproducibility. Therefore, dental development is an essential method for diagnosis and treatment planning in the orthodontic field.

Typically, it is estimated by teeth calcification development of crowns and roots on radiographs.<sup>6</sup> The Demirjian method is the most reliable and the most common method for estimating dental age that can be investigated by panoramic radiography.<sup>6</sup> The maturity stages of the dental development of mandibular permanent canines, premolars, and second molar teeth are used for assessment because their developmental stages take place within a pubertal growth period.<sup>8-9</sup> The calcification stages for mandibular permanent first molars and incisors teeth occurred before the initiation of the pubertal growth period,<sup>10</sup> while the mandibular wisdom teeth calcified after a period of pubertal growth.<sup>11</sup>

Controversy has been reported among authors who have investigated the relationship between dental development and skeletal maturation in various populations.<sup>5,15-17</sup> However, the variability caused by racial and environmental differences among different populations requires investigating this relationship in communities with different ethnic backgrounds and environmental conditions. Dental development has been proposed as a first-level diagnostic tool to estimate the timing of the pubertal growth spurt.<sup>7</sup>

Understanding the relationship between dental development and skeletal maturity is very important for dentists, orthodontists and pediatricians in order to get a reliable age estimation and prediction of pubertal growth spurt. In Yemen, no data exists about the relationship between dental development and cervical vertebral maturation. Therefore, the aim of this study was to investigate the relationship between dental development and cervical vertebral maturation in a group of Yemeni children and adolescents.

## MATERIALS AND METHODS.

This descriptive cross-sectional study was conducted on a convenient sample of Yemeni children and adolescents visiting orthodontic centers in Sana'a, Yemen. The inclusion criteria were: Yemeni individuals—aged from 8 to 18 years—requiring panoramic and lateral Cephalometric radiographs for diagnostic purposes and radiographs presenting clear anatomical details. The exclusion criteria included presence of systemic diseases that could affect the general development such as hormonal diseases, craniofacial anomalies, cleft lip and/or palate, and history of orthodontic treatment.

The study was conducted in full compliance with the ethical principles of Helsinki Declaration. It was approved by the research and ethics committee, faculty of medicine, University of Science and Technology (No.: EAC/UST127). Written consent was also obtained from all the participants after the study's objectives were fully explained and consent to use the radiographs for research purpose was obtained. The sample was collected from January to August 2018.

### Dental Maturity Assessment

Dental calcification stages were graded on digital panoramic films in accordance with the guidelines of Demirjian *et al.*,<sup>6</sup>:

**Stage A:** Calcification of single occlusal points without fusion of different calcifications.

**Stage B:** Fusion of mineralization points; the contour of the occlusal surface is recognizable.

**Stage C:** Enamel formation has been completed at the occlusal surface, and dentine formation has commenced. The pulp chamber is curved, and no pulp horns are visible.

**Stage D:** Crown formation has been completed to the level of the cement-enamel junction. Root formation has commenced. The pulp horns begin to differentiate, but the walls of the pulp chamber remain curved.

**Stage E:** The root length remains shorter than the crown height. The walls of the pulp chamber are straight, and the pulp horns have become more differentiated than in the previous stage. In molars, the radicular bifurcation has commenced to calcify.

**Stage F:** The root length is equal to or greater than the crown height. The walls of the pulp chamber now form an isosceles (equilateral) triangle. In molars, the bifurcation has developed sufficiently to give the roots a distinct form.

**Stage G:** The walls of the root canal are now parallel, but the apical end is partially open. In molars only the distal root is rated.

**Stage H:** The root apex is completely closed. The periodontal membrane surrounding the root and apex is uniform in width throughout.

The panoramic radiographs were viewed and evaluated, and then the maturity stages of the dental development of an individual's four mandibular left permanent selected teeth that included canine (C), first premolar (PM1), second premolar (PM2), and second molar (M2) were rated on an eight-stage scale (A-H). Then, they were assigned one specific stage from A to H in accordance with instructions described by Demirjian *et al.*<sup>6</sup> (Figure 1)

### Skeletal Maturity Assessment

Relevant cervical vertebrae on lateral Cephalometric radiographs were traced by acetate paper and pencil H3. The shape of the cervical vertebral bodies (C2, C3), and (C4) were visually analyzed, assessed, studied, and rated according to a six-level scale, and then assigned a specific stage from the first cervical stage to the sixth in accordance with the method of Baccetti *et al.*,<sup>14</sup> (Figure 2) which is based on two sets of variables:

1. Presence or absence of concavity in cervical vertebrae C2, C3, C4 inferior borders.
2. Morphological shape changes in bodies of cervical vertebrae C3, and C4.

**CS1:** The lower borders of all 3 vertebrae (C2-C4) are flat. The bodies of both C3 and C4 are trapezoid in shape.

**CS2:** A concavity is present at the lower border of C2. The bodies of both C3 and C4 are still trapezoid in shape.

**CS3:** Concavities at the lower borders of both C2 and C3 are present. The bodies of C3 and C4 may be either trapezoid or rectangular-horizontal in shape. The growth peak occurs the year after this stage.

**CS4:** Concavities at the lower borders of C2, C3, and C4 are present. The bodies of both C3 and C4 are rectangular-horizontal.

**CS5:** At least 1 of the bodies of C3 and C4 is square. If not square, the body of the other cervical vertebra is rectangular-horizontal.

**CS6:** At least 1 of the bodies of C3 and C4 is rectangular-vertical in shape.

The assessment of radiographs was evaluated by two investigators. Intra- and inter-observer reliability results were 0.859, 0.848 for dental development and 0.744, 0.739 for cervical vertebrae maturity, respectively.

### Statistical Analysis

All the data were analyzed using "Statistical Package for the Social Sciences" (SPSS version 20, IBM). Descriptive statistics were done to determine the means and standard deviations of the chronological ages for the six stages of CVM. The frequency and percentage distribution of the stages of calcification were evaluated for both male and female subjects. Spearman Rank-Order Correlation Coefficient was used to assess the correlation between dental developments and CVM. The accepted level of significance was set at  $p < 0.05$ .

## RESULTS.

A total of 207 subjects -85 males and 122 females aged between 8 and 18 years- participated in this study. The individuals were divided into two age subgroups: 8-13 years and 14-18 years. (Figure 3)

Chronological age distributions of each maturity stage of cervical vertebrae for both genders are illustrated in Table 1. Girls showed earlier cervical vertebral maturity compared to boys. There were statistically significant differences between boys and girls in all CVM stages except for CVM stage 6.

All associations among maturity stages of dental development and cervical vertebrae were statistically significant ( $p < 0.001$ ). The levels of correlation coefficients for an individual's teeth ranged from 0.686 to 0.873 and 0.787 to 0.871 for females and males respectively.

The sequence of teeth in order from highest to lowest correlation coefficient with CVM was second molars, second premolars, first premolars, and canines in both genders. The second molars teeth had the strongest

positive correlation with CVM, whereas the canines had the lowest correlation in both genders. (Table 2)

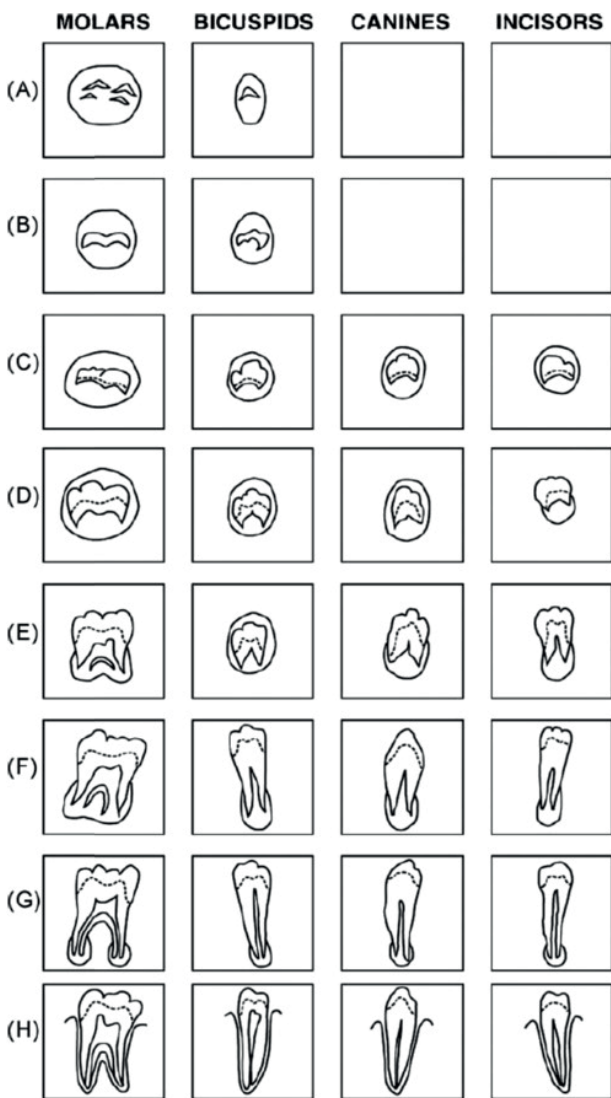
The percentage distributions of the relationships between the maturity stages of the studied four mandibular teeth and the stages of CVM for both genders. For CVM stage 1, the stage F of the first premolars and the stage G of the canines demonstrated the highest percentage distribution of 81.2% and 60.9% for females and males, respectively. For CVM stage 2, the stage G of the first premolars presented the strongest percentage distribution of 57.9% and 77.8% for females and males, respectively. For CVM stage 3, the first premolar stage G for females showed the highest percentage distribution of 73.3%. The canine stage H showed the highest

percentage distribution of 80.0% in males. (Table 3)

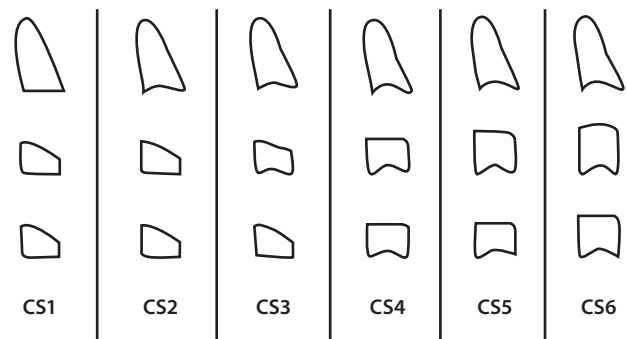
For CVM stage 4, in female subjects, root calcification was nearly complete (stage H) for the first premolar and the canine –69.2% and 96.2% respectively. For males, the root development of the first premolar and the canine was mostly completed (stage H) in most of the subjects– 70.0% and 100.0%, respectively.

The majority of the relevant investigated teeth were well formed in CVM stage 5. For both genders, the closing process of the roots was completely finished for the canine and first premolar stage H. For CVM stage 6, no calcification stages D, E and F were seen and the root calcification was closed and complete (Stage H; 100.0%) for all canines and first premolars for both genders.

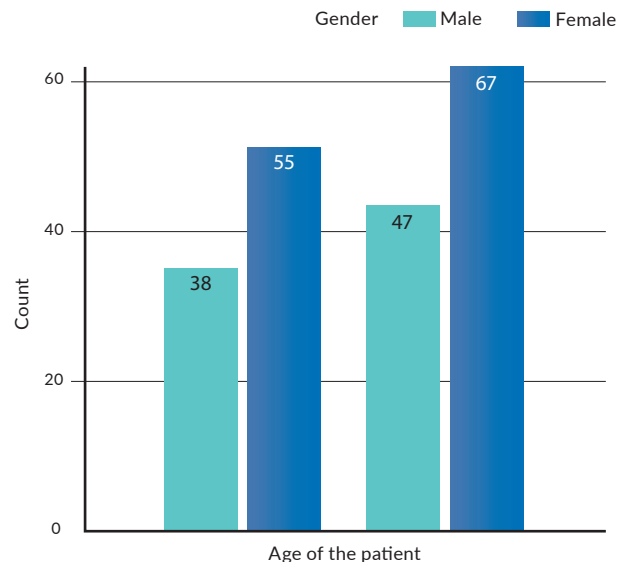
**Figure 1.** Diagrammatic representation of Demirjian's eight stages of dental development (A to H) (Demirjian et al.,1973).



**Figure 2.** Cervical vertebrae stages-diagrammatic illustration (Baccetti et al.,14).



**Figure 3.** Age distribution of the sample into two different age subgroup.



**Table 1.** Chronological ages distribution for each maturity stage of cervical vertebrae for both genders.

| CVM stage | Gender | Number of subjects | Mean age | Std. Deviation | p-value |
|-----------|--------|--------------------|----------|----------------|---------|
| Stage 1   | Male   | 23                 | 10.52    | 1.50           | 0.00    |
|           | Female | 16                 | 9.38     | 1.08           |         |
| Stage 2   | Male   | 18                 | 13.33    | .76            | 0.00    |
|           | Female | 19                 | 11.68    | .88            |         |
| Stage 3   | Male   | 15                 | 13.87    | .83            | 0.00    |
|           | Female | 15                 | 12.93    | 1.10           |         |
| Stage 4   | Male   | 10                 | 15.30    | .67            | 0.00    |
|           | Female | 26                 | 14.15    | 1.00           |         |
| Stage 5   | Male   | 12                 | 16.58    | 1.08           | 0.03    |
|           | Female | 21                 | 15.71    | .90            |         |
| Stage 6   | Male   | 7                  | 17.29    | .48            | 0.68    |
|           | Female | 25                 | 17.08    | .81            |         |
| Total     |        | 207                |          |                |         |

**Table 2.** Correlation coefficients among the maturity stages of cervical vertebrae and dental development for Yemeni according to sex.

| Tooth           | Male  |         | Female |         |
|-----------------|-------|---------|--------|---------|
|                 | R     | p-value | R      | p-value |
| Canine          | 0.787 | 0.000   | 0.686  | 0.000   |
| First premolar  | 0.822 | 0.000   | 0.817  | 0.000   |
| Second premolar | 0.836 | 0.000   | 0.867  | 0.000   |
| Second molar    | 0.871 | 0.000   | 0.873  | 0.000   |

**Table 3.** Correlation coefficients among the maturity stages of cervical vertebrae and dental development for Yemeni according to sex.

| Dental stage | Canine |      | First premolar |      |      |      | Second premolar |      |      |      | Second molar |      |      |      |        |      |
|--------------|--------|------|----------------|------|------|------|-----------------|------|------|------|--------------|------|------|------|--------|------|
|              | Male   |      | Female         |      | Male |      | Female          |      | Male |      | Female       |      | Male |      | Female |      |
|              | N      | %    | N              | %    | N    | %    | N               | %    | N    | %    | N            | %    | N    | %    | N      | %    |
| D            | 0      | 0.0  | 0              | 0.0  | 0    | 0.0  | 0               | 0.0  | 0    | 0.0  | 0            | 0.0  | 0    | 0.0  | 0      | 0.0  |
| E            | 0      | 0.0  | 0              | 0.0  | 0    | 0.0  | 0               | 0.0  | 0    | 0.0  | 0            | 0.0  | 0    | 0.0  | 2      | 13.3 |
| F            | 0      | 0.0  | 0              | 0.0  | 0    | 0.0  | 2               | 13.3 | 2    | 13.3 | 5            | 33.3 | 4    | 26.7 | 6      | 40.0 |
| G            | 3      | 20.0 | 4              | 26.7 | 7    | 46.7 | 11              | 73.3 | 9    | 60.0 | 10           | 66.7 | 11   | 73.3 | 7      | 46.7 |
| H            | 12     | 80.0 | 11             | 73.3 | 8    | 53.3 | 2               | 13.3 | 4    | 26.7 | 0            | 0.0  | 0    | 0.0  | 0      | 0.0  |
| Total        | 15     | 100  | 15             | 100  | 15   | 100  | 15              | 100  | 15   | 100  | 15           | 100  | 15   | 100  | 15     | 100  |

## DISCUSSION.

To the best of our knowledge, this is the first study that has assessed the relationship between dental development and skeletal maturity using the CVM assessment method with a sample of Yemenis. Overall, the results have showed a statistically significant positive correlation between dental maturity of the studied mandibular teeth and CVM ( $p < 0.01$ ).

The second molars teeth showed the strongest positive correlation with CVM, whereas canines had the lowest correlation for both genders. Moreover, female

subjects showed earlier cervical vertebral maturity compared to their male counterparts.

The findings of the study are in line with most of the previous published studies, which have reported a significant positive correlation between dental development and CVM index,<sup>9,10,20-27</sup> confirming that cervical vertebral maturation can be a viable guideline for the prediction of the pubertal growth spurt.

Moreover, similarly to studies conducted by Cossellu *et al.*,<sup>18</sup> and Uysal *et al.*,<sup>8</sup> this study revealed that the mandibular second molar maturation had the strongest

correlation with CVM. Cossellu *et al.*,<sup>18</sup> have suggested that second molars are believed to be the most appropriate teeth to be considered for identifying the correlation between dental maturity and skeletal maturity, given the possible various limitations of other teeth, especially canines, according to Cossellu *et al.*,<sup>18</sup>

However, other investigators have reported different results. For example, the second premolar showed the highest correlation among Croatian *et al.*,<sup>19</sup> populations, while the first premolar showed the highest correlation among Iranian subjects.<sup>13</sup>

Such variations can be attributed to various factors including ethnic, nutritional, socioeconomic and environmental factors. Another important finding in this study is that females showed earlier maturity of cervical vertebrae than males. This finding is also consistent with most of the previous studies that have been conducted by Howell on British subjects,<sup>22</sup> Cisternas *et al.*,<sup>24</sup> in Chile and Hassan and Abo-affan in Sudan.<sup>25</sup>

This is clinically important if the growth process is to be utilized to help in malocclusion correction, whereby orthodontic therapy by functional appliances needs to be started earlier in Yemeni females than males. Interestingly, the findings of this study has also showed that the dental development of males was more advanced than that of females in relation to the stages of skeletal maturity.

The results are also in agreement with the studies conducted by Uysal *et al.*,<sup>17</sup> on Turkish subjects and Howell *et al.*,<sup>22</sup> on British subjects. As noted earlier, this is the first study conducted on Yemeni subjects, which has shed some light on the association between dental maturity and skeletal maturity.

However, the study has some limitations such as the small size of the sample, which should be considered when interpreting the results. Therefore, further studies with large sample sizes and even distribution of age and gender groups are highly recommended in order to draw more precise results.

## CONCLUSION.

This study has found a moderate to strong correlation between dental calcification and CVM. The left mandibular second molars presented the highest correlations in both genders, which can be used as markers when considering doing a simple first-level diagnostic test to determine the skeletal maturity.

Furthermore, the results showed that the transitional

time between stages F and G in female subjects and stage G in male's subjects for the left mandibular second molar teeth signify the beginning of a peak growth period. Additionally, dental development was more advanced in males compared to females in relation to the stages of skeletal maturity.

---

**Conflict of interests:** The authors declare no conflicts of interest.

**Ethics approval:** Approved by the Medical ethical Committee Approval, Universidad of Science and Technology. No. EAC/UST127

**Funding:** None.

**Authors' contributions:** All authors approved the final draft of the manuscript. Aldhorae: Conceptual framework; Aldhorae, Al-Aunhomi: Designing the study; Al-Aunhomi A: Data collection and initial handling. Manuscript writing: Aldhorae, Al-Aunhomi; Al-Ashtal, Ishaq: Manuscript editing; Al-Labani, Al-Maweri: Data analysis; Aldhorae Khalid: Manuscript revision.

**Acknowledgements:** None.

## REFERENCES.

1. Gupta M, Divyashree R, Abhilash PR, Bijle MNA, Murali, KV. Correlation between Chronological Age, Dental Age and Skeletal Age among Monozygotic and Dizygotic Twins. *J Int Oral Health*.2013;3(1):16-22.
2. Baccetti T, Franchi L, McNamara JA Jr. An improved version of the cervical vertebral maturation (CVM) method for the assessment of mandibular growth. *Angle Orthod*. 2002;72(4):316-23.
3. Proffit WR. *Contemporary Orthodontics - 4th Ed*, MOSBY Elsevier.2007.
4. Hassel B, Farman AG. Skeletal maturation evaluation using cervical vertebrae. *Am J Orthod Dentofacial Orthop*. 1995; 107(1):58-66.
5. Flores-Mir C, Burgess CA, Champney M, Jensen RJ, Pitcher MR, Major PW. Correlation of skeletal maturation stages determined by cervical vertebrae and hand-wrist evaluations. *Angle Orthod*. 2006;76(1):1-5.
6. Demirjian A, Goldstein H, Tanner J M. A new system of dental age assessment. *Human Biology*.1973; 45 (2), 211-27.
7. Krailassiri, S, Anuwongnukroh N, Dechkunakorn S. Relationships between dental calcification stages and skeletal maturity indicators in Thai individuals. *Angle Orthodontist*. 2002;72 (2), 155-66
8. Uysal T, Sari Z, Ramoglu SI, Basciftci FA. Relationships between dental and skeletal maturity in Turkish subjects. *Angle Orthod*. 2004;74(5):657-64.
9. Kumar S, Singla A, Sharma R, Viridi MS, Anupam A, Mittal B. Skeletal maturation evaluation using mandibular second molar calcification stages. *Angle Orthod*. 2012;82(3):501-6.
10. Başaran G, Ozer T, Hamamci N. Cervical vertebral and dental maturity in Turkish subjects. *Am J Orthod Dentofacial Orthop*. 2007;131(4):447.e13-20.
11. Engström C, Engström H, Sagne S. Lower third molar development in relation to skeletal maturity and chronological age. *Angle Orthod*. 1983;53(2):97-106.
12. Kopecky GR, Fishman LS. Timing of cervical headgear treatment based on skeletal maturation. *Am J Orthod Dentofacial Orthop*. 1993;104(2):162-9.
13. Valizadeh S, Eil N, Ehsani S, Bakhshandeh H. Correlation Between Dental and Cervical Vertebral Maturation in Iranian Females. *Iran J Radiol*. 2012;10(1):1-7
14. Baccetti T, Franchi L, McNamara Jr JA. The cervical vertebral maturation (CVM) method for the assessment of optimal treatment timing in dentofacial orthopedics. *Seminars in Orthodontics*. 2005;11 (3), 119-29
15. Chen J, Hu H, Guo J, Liu Z, Liu R, Li F, Zou S. Correlation between dental maturity and cervical vertebral maturity. *Oral Surg Oral Med Oral Pathol Oral Radiol Endod*. 2010;110(6):777-83.
16. McNamara JA, Bookstein FL, Shaughnessy TG. Skeletal and dental changes following functional regulator therapy on class II patients. *Am J Orthod*. 1985;88(2):91-110.
17. Uysal T, Ramoglu SI, Basciftci FA, Sari Z. Chronologic age and skeletal maturation of the cervical vertebrae and hand-wrist: is there a relationship? *Am J Orthod Dentofacial Orthop*. 2006;130 (5):622-628.
18. Cossellu G, Biagi R, Pisani L, Barbieri V, Farronato G. Relationship between mandibular second molar calcification stages and cervical vertebrae maturity in Italian children and young adults. *Eur J Paediatr Dent*. 2014;15(4):355-9.
19. Srkoč T, Meštrović S, Anič-Milošević S, Šljaj M. Association between dental and skeletal maturation stages in Croatian subjects. *Acta clinica Croatica*. 2015;54(4.):445-52.
20. Lecca-Morales RM, Carruitero MJ. Relationship between dental calcification and skeletal maturation in a Peruvian sample. *Dental Press J Orthod*. 2017;22(3):89-96.
21. Perinetti G, Contardo L, Gabrieli P, Baccetti T, Di Lenarda R. Diagnostic performance of dental maturity for identification of skeletal maturation phase. *European Journal of Orthodontics*. 2012;34 (4): 487-92
22. Howell JL. A study into the relationship between dental development and cervical vertebral maturation in UK subjects. [Thesis], 2015. University of Birmingham.
23. Servello DF, Fallis DW, Alvetro L. Analysis of Class II patients, successfully treated with the straight-wire and Forsus appliances, based on cervical vertebral maturation status. *Angle Orthodontist*. 2015;85(1):80-6.
24. Cisternas A, Morales R, Ramirez V, Real AD, Oyonarte, R. Diagnostic assessment of skeletal maturity through dental maturation in Hispanic growing individuals. *APOS Trends Orthod*. 2017;7:35-40
25. Hasan BM, Abu-affan AH. Correlation between Chronological Age, Dental Age and Skeletal Maturity in a Sample of Sudanese Children. *Global J Med Res*.2016; 16(1):12-21.
26. Nestman, TS, Marshall SD, Qian F, Holton N, Franciscus RG, Southard, TE. Cervical vertebrae maturation method morphologic criteria: poor reproducibility. *Am J Orthod Dentofacial Orthop*. 2011;140(2):182-8.
27. Mini MM, Thomas V, Bose T. Correlation between Dental Maturity by Demirjian Method and Skeletal Maturity by Cervical Vertebral Maturity Method using Panoramic Radiograph and Lateral Cephalogram. *J Indian Acad Oral Med Radiol*. 2017;29(4):362-7.