

## Diagnostic accuracy of a charge-coupled device and a photostimulable phosphor plate in detection of non-cavitated proximal caries.

Ana Paola Trevejo-Bocanegra,<sup>1</sup> Alejandro Hidalgo<sup>2</sup> & Jorge Beltrán.<sup>1</sup>

**Affiliations:** <sup>1</sup>Universidad Peruana Cayetano Heredia, Lima, Perú. <sup>2</sup>Universidad de Talca, Talca, Chile.

**Corresponding author:** Ana Paola Trevejo-Bocanegra. Av. Honorio Delgado 430, Urb. Ingeniería, Lima – Perú. Phone: (51-1) 3190000. E-mail: ana.trevejo.b@upch.pe

**Receipt:** 12/26/2017 **Revised:** 01/17/2018  
**Acceptance:** 02/15/2018 **Online:** 02/15/2018

**Conflict of interests:** The authors declare no conflicts of interest.

**Ethics approval:** Ethics Committee of the Universidad Peruana Cayetano Heredia (No. 594-26-15).

**Funding:** Self-funded by the authors.

**Authors' contributions:** Ana Trevejo- Bocanegra made substantial contributions to the study design, data analysis, drafting and critical revision of the manuscript for important intellectual content and final approval of the final version; Alejandro Hidalgo and Jorge Beltrán made substantial contributions to the analysis and interpretation of data, critical revision of the manuscript for important intellectual content and final approval of the final version.

**Acknowledgements:** None.

**Cite as:** Trevejo-Bocanegra AP, Hidalgo A & Beltrán J. Diagnostic accuracy of a charge-coupled device and a photostimulable phosphor plate in detection of non-cavitated proximal caries. *J Oral Res* 2018; 7(2):61-69. doi:10.17126/joralres.2018.017

**Abstract:** Objective: The aim of this study was to compare the diagnostic accuracy of two direct digital radiography systems: the charge-coupled device (CCD) XIOS XG Sirona® and the photostimulable storage phosphor (PSP) VistaScan DürrDental®, in the detection of non-cavitated proximal caries lesions. Materials and methods: in this experimental and cross-sectional study 112 proximal surfaces from 27 molars and 31 premolars with or without proximal caries lesions were evaluated and randomly allocated in a study unit. Bitewing radiographs were acquired with a CCD XIOS XG and with the PSP VistaScan. A single X-ray unit was used for both systems. Radiographic images were assessed independently by two calibrated radiologists. Histological evaluation on a stereomicroscope was used as gold standard. Results: Sensitivity values were found to be 0.35 for CCD and 0.31 for PSP. Specificity values were found to be similar for both systems (0.867). Az values showed a low diagnostic accuracy for both sensors: 0.61 for CCD and 0.59 for PSP, no statistical difference was found between these two values ( $p=0.78$ ). Conclusion: Both digital radiology systems have a high diagnostic accuracy to detect sound surfaces but low diagnostic accuracy to detect proximal carious lesions.

**Keywords:** Sensitivity; specificity; dental radiography; dental caries.

### INTRODUCTION.

Caries is a process of tooth demineralization, which allows a greater penetration of X-rays resulting in radiolucency, unlike the radiopacity of sound tooth tissue.<sup>1-3</sup> However, histological changes during the initial demineralization are not pronounced enough to be detected in a radiographic image. Therefore, the detection of non-cavitated carious lesions is difficult.<sup>4</sup> Different detection methods of early caries lesions with different levels of applicability and accuracy have been developed, such as visual inspection, conventional and digital radiography, transillumination, electrical conductivity and laser.<sup>5</sup>

Technology development has enabled radiographic images to be acquired and displayed through a computer. Digital radiology systems are used currently as an alternative to conventional radiography due to such advantages as: allowing the visualization of an image in a few seconds, storing information in digital formats, the availability of tools allowing a high-quality display, chemical processing not required and reduced radiation doses.<sup>2,6</sup>

There are two types of digital image sensors: 1) solid state detectors: charge-coupled device (CCD) and complementary metal oxide semiconductor (CMOS), and 2) photostimulable phosphor plate (PSP). The CCD is an integrated circuit with coupled capacitors; each of them can transfer its load to other capacitors in the circuit. Charge packets represent the latent image.<sup>2</sup> The PSP absorbs and stores energy, which is released as phosphorescence with stimulation from another light of appropriate wave length. PSP have nearly the same size and flexibility as conventional films.<sup>2,7</sup>

Previous studies have reported sensitivity (0.14-0.16), specificity (0.89-0.94) and accuracy (0.60-0.88) of digital radiology systems in detecting proximal carious lesions.<sup>8-10</sup> However, predictive values to determine the usefulness of these systems in a clinical setting are less often reported. The aim of this study was to determine the diagnostic accuracy of two digital radiology systems (CCD and PSP) in the detection of proximal carious lesions.

## MATERIALS AND METHODS.

### Study design and ethical considerations

This experimental study was approved by the Ethics Committee of the Universidad Peruana Cayetano Heredia (No. 594-26-15). A sample of 112 extracted human permanent teeth (51 molars and 61 premolars) with sound proximal surfaces or with non-cavitated proximal carious lesions were used. All samples were obtained from the Dentistry Faculty where teeth were extracted for prosthetic or orthodontic reasons. The samples were sterilized in an autoclave for 40 minutes at 240°F (115.6°C) and 20 psi (1.36 atmosphere) to prevent bacterial growth. The samples were then stored in saline solution. Teeth with fractures or restorations were not included.

### Eligibility criteria

Each tooth was selected by a single specialist in aesthetic and restorative dentistry with more than 10 years of experience. This specialist decided on the inclusion of each tooth based on ICDAS-II (International Caries Detection and Assessment System) criteria by reviewing each dental dry surface with a 2X magnifying glass. A code 0 was given to sound surfaces and codes 1 and 2 to

surfaces with non-cavitated carious lesion.<sup>11</sup>

### Study unit

Selected teeth were coded and randomly allocated into 14 groups of 8 teeth each. A study unit was created with the teeth placed on an acrylic plate (6x2x5cm.) in 2 rows of 4 premolars and molars. The crown was left outside of the acrylic plate and roots placed inside the plate. There was a 0.5cmx0.5cm groove between the two rows to place the digital receptor.

The teeth were placed without proximal contact. Although the teeth did not have natural contact, the vestibular and palatal/lingual surfaces were placed with the same orientation and the mesio-distal axis remained parallel to the unit's groove to ensure the correct image formation.

### Digital radiography image acquisition

Bitewing radiographs were acquired with a CCD XIOS XG (Sirona®, Bensheim, Germany) and with a PSP VistaScan (DürrDental®, Bietigheim-Bissingen, Germany). A single X-ray unit was used for both systems (Intra ProX, Planmeca, Helsinki, Finland), with 70kV, 8mA, 0.2 seconds and a total filtration of 2.5mm. The X-ray tube was placed 20cm from the study unit.

The CCD receptor and PSP were placed in the study unit's groove to ensure the geometrical reproducibility of the radiography. The vertical angulation was identical in each radiographic image. The upper line of the X-ray tube indicating the central ray was used to orient it perpendicular to the sensor. For the PSP a No2 receptor was used and immediately scanned using the VistaScan Combi View (DürrDental®, Bietigheim-Bissingen, Germany).

All the acquired images were stored in .JPG format and saved with a code (Figure 1A, 1B).

### Radiographic evaluation

Two oral and maxillofacial radiologists (AT and JB) with more than 10 years of experience independently examined each image twice. Evaluations were performed considering the average width of the premolars. These radiologists evaluated mesial and distal surfaces and filled the registration table in Excel v. 10.0 (Microsoft Corporation, Redmond, WA, USA), per the following radiographic classification: R0: sound, R1: lesion in the outer half of enamel, R2: lesion in the inner half of the

enamel and R3: lesion in the outer half of dentin.<sup>12</sup>

The radiologists were blind to the digital system being evaluated. All digital images were evaluated using the same computer, with monitor resolution of 1400x900 pixels. The room for the image evaluations had standardized low environmental noise and lighting observation conditions.

#### Stereomicroscope image acquisition

To determine carious lesion depth, observation on a stereomicroscope is widely used as the gold standard. The study units were cut with a high-speed grinding machine DEMCO E-96 (Dental Maintenance Co. Inc, Bonsall, CA, USA) with a double-sided diamond cutting disc Giflex-TR (Bredent GmbH & Co.KG, Senden, Germany) 30mm in diameter, 0.3mm wide. Each tooth was separated from the study unit and was cut separately; the cuttings were performed mesio-distally in the crown where the caries lesion was located, even when there was a sound surface in the same tooth. In sound teeth the axis of occlusal fissure was followed. Thus, 500µm wide specimens were obtained. The final polishing was performed with sandpaper.

Then, the samples were placed in a container with saline solution to maintain their hydration until they were observed at the microscope. A Leica DFC425 stereomicroscope with EC3 camera (Leica, Wetzlar, Germany) with a 3x magnification was used (Figure 1C).

#### Histologic evaluation

A specialist in oral pathology, blinded to the method

of radiograph acquisition and to results of that stage, observed once the mesial and distal surfaces. This specialist filled the registration table in Excel version 10.0 (Microsoft Corporation, Redmond, WA, USA), according to the radiographic classification described above.

#### Data analyses

The sensitivity, specificity, positive (PPV) and negative (NPV) predictive values, and accuracy of each system were calculated. The analyses were performed using the SPSS statistical program version 22.0 (IBM Corporation, Armonk, NY, USA) for Windows.

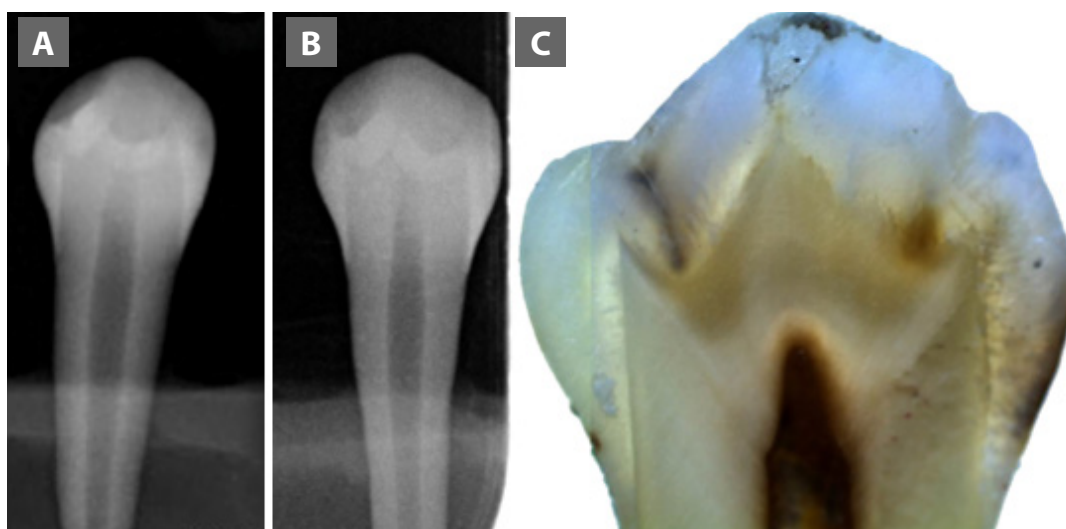
The data registered by the two radiologists were randomly pooled by this statistical program to calculate descriptive and analytic statistics values.

The absolute and relative values for the detection of carious lesions with both systems and histology frequencies were described in double-entry tables. In addition, the kappa value was calculated in order to establish the correlation between lesion detection by the CCD and PSP systems and by histology.<sup>13</sup>

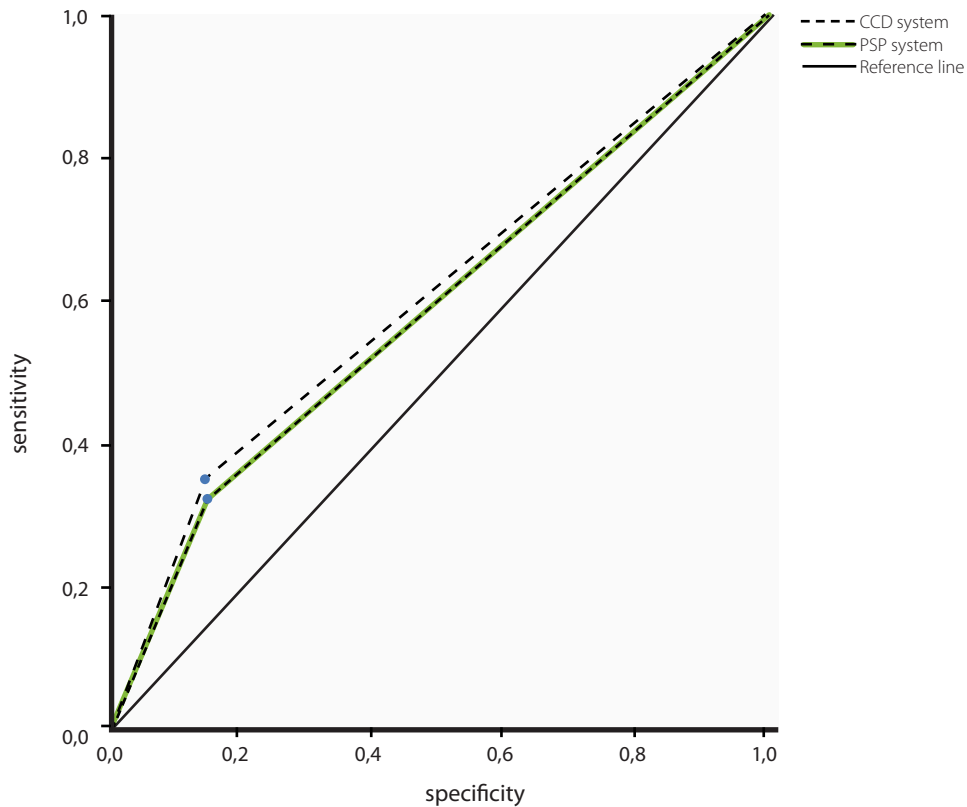
Sensitivity and specificity were illustrated in a receiver operating characteristic (ROC) curve. The area under the ROC curve (Az value) was used to compare the diagnostic accuracy of the digital radiology systems.<sup>12,14</sup>

The comparison between these areas was calculated through the DeLong test on EPIDAT version 3.1 statistical software (Pan American Health Organization-PAHO). The significance level was set at  $p < 0.05$ .

**Figure 1.** Images of the same tooth: **A.** CCD system image, **B.** PSP system image. **C.** Histological section.



**Figure 2.** Receiver operating characteristic (ROC) curve of radiology digital systems in proximal carious lesions. 95% confidence interval.



**Table 1.** Frequency distribution of proximal carious lesions detection per digital radiology system, tooth and surface.

METHOD			DENTAL CARIES DETECTION									
			R0		R1		R2		R3		R4	
			n	%	n	%	N	%	n	%	n	%
HISTOLOGY	Tooth	Premolar	9	8.04	18	16.07	19	16.96	10	8.93	5	4.46
		Molar	6	5.36	26	23.21	15	13.39	2	1.79	2	1.79
	Surface	Mesial	6	5.36	22	19.64	22	19.64	4	3.57	3	2.68
		Distal	9	8.04	22	19.64	12	10.71	8	7.14	4	3.57
		<b>Total</b>	<b>15</b>	<b>13.39</b>	<b>44</b>	<b>39.29</b>	<b>34</b>	<b>30.36</b>	<b>12</b>	<b>10.71</b>	<b>7</b>	<b>6.25</b>
CCD	Tooth	Premolar	37	33.04	14	12.50	10	8.93	0	0.00	0	0.00
		Molar	39	34.82	6	5.36	6	5.36	0	0.00	0	0.00
	Surface	Mesial	36	32.14	14	12.50	7	6.25	0	0.00	0	0.00
		Distal	40	35.71	6	5.36	9	8.04	0	0.00	0	0.00
		<b>Total</b>	<b>76</b>	<b>67.86</b>	<b>20</b>	<b>17.86</b>	<b>16</b>	<b>14.29</b>	<b>0</b>	<b>0.00</b>	<b>0</b>	<b>0.00</b>
PSP	Tooth	Premolar	41	36.61	14	12.50	5	4.46	1	0.89	0	0.00
		Molar	39	34.82	8	7.14	2	1.79	1	0.89	1	0.89
	Surface	Mesial	42	37.50	9	8.04	5	4.46	0	0.00	1	0.89
		Distal	38	33.93	13	11.61	2	1.79	2	1.79	0	0.00
		<b>Total</b>	<b>80</b>	<b>71.43</b>	<b>22</b>	<b>19.64</b>	<b>7</b>	<b>6.25</b>	<b>2</b>	<b>1.79</b>	<b>1</b>	<b>0.89</b>

R0: Sound. R1: Lesion in the outer half of enamel. R2: Lesion in the inner half of enamel. R3: Lesion in the outer half of dentin. R4: Lesion in the inner half of dentin; n: Absolute frequency, %: Relative frequency.

**Table 2.** Frequency distribution of proximal carious lesions detection per digital radiology system, tooth and surface.

SYSTEM			R0		R1				R2				R3				R4				Kappa			
			A		NA		A		NA		A		NA		A		NA		A		NA		Value	p
			N	%	n	%	n	%	N	%	n	%	N	%	n	%	n	%	n	%	n	%		
CCD	Tooth	Premolar	7	46.67	2	13.33	5	11.36	13	29.55	3	8.82	16	47.06	0	0.00	10	83.33	0	0.00	5	71.43	0.05	0.41
		Molar	6	40.00	0	0.00	2	4.55	24	54.55	2	5.88	13	38.24	0	0.00	2	16.67	0	0.00	2	28.57	0.01	0.78
	Surface	Mesial	6	40.00	0	0.00	6	13.64	16	36.36	2	5.88	20	58.82	0	0.00	4	33.33	0	0.00	3	42.86	0.05	0.42
		Distal	7	46.67	2	13.33	1	2.27	21	47.73	3	8.82	9	26.47	0	0.00	8	66.67	0	0.00	4	57.14	<0.01	0.97
		Total	13	86.67	2	13.33	7	15.91	37	84.09	5	14.71	29	85.29	0	0.00	12	100.00	0	0.00	7	100.00	0.02	0.55
PSP	Tooth	Premolar	7	46.67	2	13.33	4	9.09	14	31.82	1	2.94	18	52.94	0	0.00	10	83.33	0	0.00	5	71.43	<0.01	0.97
		Molar	6	40.00	0	0.00	4	9.09	22	50.00	1	2.94	14	41.18	1	8.33	1	8.33	0	0.00	2	28.57	0.06	0.19
	Surface	Mesial	6	40.00	0	0.00	4	9.09	18	40.91	2	5.88	20	58.82	0	0.00	4	33.33	0	0.00	3	42.86	0.05	0.35
		Distal	7	46.67	2	13.33	4	9.09	18	40.91	0	0.00	12	35.29	1	8.33	7	58.33	0	0.00	4	57.14	<0.01	0.95
		Total	13	86.67	2	13.33	8	18.18	36	81.82	2	5.88	32	94.12	1	8.33	11	91.67	0	0.00	7	100.00	0.03	0.50

R0: Sound. R1: Lesion in the outer half of enamel. R2: Lesion in the inner half of enamel. R3: Lesion in the outer half of dentin. R4: Lesion in the inner half of dentin. A: Agreement. NA: No agreement. n: Absolute frequency. %: Relative frequency. Kappa: Concordance Kappa analysis.

**Table 3.** CCD and PSP sensitivity and specificity in proximal carious lesions detection per teeth and surface evaluated.

SYSTEM			HISTOLOGICAL DIAGNOSIS						Sensitivity	Specificity	PPV	PNV	Accuracy	
			Caries		No caries		Total							
			n	%	n	%	n	%						
CCD	Tooth	Premolar	Caries	22	19.64	2	1.79	24	39.34	0.42	0.78	0.92	0.19	0.48
			No caries	30	26.79	7	6.25	37	60.66					
			<b>Total</b>	<b>52</b>	<b>85.25</b>	<b>9</b>	<b>14.75</b>	<b>61</b>	<b>100.00</b>					
		Molar	Caries	12	10.71	0	0.00	12	23.53					
			No caries	33	29.46	6	5.36	39	76.47					
			<b>Total</b>	<b>45</b>	<b>88.24</b>	<b>6</b>	<b>11.76</b>	<b>51</b>	<b>100.00</b>					
	Surface	Mesial	Caries	21	18.75	0	0.00	21	36.84	0.41	1.00	1.00	0.17	0.47
			No caries	30	26.79	6	5.36	36	63.16					
			<b>Total</b>	<b>51</b>	<b>89.47</b>	<b>6</b>	<b>10.53</b>	<b>57</b>	<b>100.00</b>					
		Distal	Caries	13	11.61	2	1.79	15	27.27					
			No caries	33	29.46	7	6.25	40	72.73					
			<b>Total</b>	<b>46</b>	<b>83.64</b>	<b>9</b>	<b>16.36</b>	<b>55</b>	<b>100.00</b>					
<b>Total</b>	<b>Caries</b>	<b>34</b>	<b>30.36</b>	<b>2</b>	<b>1.79</b>	<b>36</b>	<b>32.14</b>	<b>0.35</b>	<b>0.87</b>	<b>0.94</b>	<b>0.17</b>	<b>0.42</b>		
<b>No caries</b>	<b>63</b>	<b>56.25</b>	<b>13</b>	<b>11.61</b>	<b>76</b>	<b>67.86</b>								
<b>Total</b>	<b>97</b>	<b>86.61</b>	<b>15</b>	<b>13.39</b>	<b>112</b>	<b>100.00</b>								
PSP	Tooth	Premolar	Caries	18	16.07	2	1.79	20	32.79	0.35	0.78	0.90	0.17	0.41
			No caries	34	30.36	7	6.25	41	67.21					
			<b>Total</b>	<b>52</b>	<b>85.25</b>	<b>9</b>	<b>14.75</b>	<b>61</b>	<b>100.00</b>					
		Molar	Caries	12	10.71	0	0.00	12	23.53					
			No caries	33	29.46	6	5.36	39	76.47					
			<b>Total</b>	<b>45</b>	<b>88.24</b>	<b>6</b>	<b>11.76</b>	<b>51</b>	<b>100.00</b>					
	Surface	Mesial	Caries	15	13.39	0	0.00	15	26.32	0.29	1.00	1.00	0.14	0.37
			No caries	36	32.14	6	5.36	42	73.68					
			<b>Total</b>	<b>51</b>	<b>89.47</b>	<b>6</b>	<b>10.53</b>	<b>57</b>	<b>100.00</b>					
		Distal	Caries	15	13.39	2	1.79	17	30.91					
			No caries	31	27.68	7	6.25	38	69.09					
			<b>Total</b>	<b>46</b>	<b>83.64</b>	<b>9</b>	<b>16.36</b>	<b>55</b>	<b>100.00</b>					
<b>Total</b>	<b>Caries</b>	<b>30</b>	<b>26.79</b>	<b>2</b>	<b>1.79</b>	<b>32</b>	<b>28.57</b>	<b>0.31</b>	<b>0.87</b>	<b>0.94</b>	<b>0.16</b>	<b>0.38</b>		
<b>No caries</b>	<b>67</b>	<b>59.82</b>	<b>13</b>	<b>11.61</b>	<b>80</b>	<b>71.43</b>								
<b>Total</b>	<b>97</b>	<b>86.61</b>	<b>15</b>	<b>13.39</b>	<b>112</b>	<b>100.00</b>								

n: Absolute frequency. %: Relative frequency. PPV: Predictive positive value. PNV: Predictive negative value.

**Table 4.** Az values of radiology digital systems per tooth and surface evaluated.

		SYSTEM	Az	CI 95%	SE
Tooth	Premolar	CCD	0.60	0.44 - 0.76	0.08
		PSP	0.56	0.40 - 0.72	0.08
	Molar	CCD	0.63	0.57 - 0.70	0.03
		PSP	0.63	0.57 - 0.70	0.03
Surface	Mesial	CCD	0.71	0.64 - 0.77	0.03
		PSP	0.65	0.58 - 0.71	0.03
	Distal	CCD	0.53	0.37 - 0.69	0.08
		PSP	0.55	0.39 - 0.71	0.08
Total	CCD	0.61	0.51 - 0.71	0.05	
	PSP	0.59	0.49 - 0.69	0.05	

Az: Area under the curve. CI 95%: Confidence interval 95%. SE: Standard error.

\*: DeLong test: premolars ( $p=0.74$ ), molars ( $p=1.00$ ), mesial ( $p=0.21$ ), distal ( $p=0.85$ ) and total ( $p=0.78$ ).

## RESULTS.

During the teeth preparation for histological evaluation, 33 specimens with deep occlusal caries lesion were lost, finally remaining 27 molars and 31 premolars. Thus, a total of 112 surfaces (57 mesial and 55 distal) were evaluated. The distribution frequency in detecting proximal caries lesion with two digital radiology systems and histology is shown in Table 1.

Agreement in detecting proximal carious lesions for both systems regarding histology is shown in Table 2. Sensitivity and specificity of both systems are shown in Table 3. Figure 2 shows the sensitivity and 1- specificity relationship between both systems through the ROC curve. The Az values of both systems are shown in Table 4.

## DISCUSSION.

The present study evaluated the diagnostic accuracy of two radiology digital systems in the detection of non-cavitated proximal caries. The systems evaluated were CCD XIOS XG (Sirona®, Bensheim, Germany) and PSP VistaScan (DürrDental®, Bietigheim-Bissingen, Germany).

Like conventional intraoral radiographs, CCD and PSP systems have also demonstrated difficulties in detecting non-cavitated proximal carious lesions.<sup>9</sup> This is because small amounts of demineralization in enamel caries are not detected by radiographs.

In the present research, systems with different resolutions (16 lp/mm for CCD, and 20 lp/mm for PSP) were used, and the difference between their diagnostic accuracy was found to be non-significant. In agreement with our work, Senel *et al.*,<sup>8</sup> studied the accuracy of CCD, PSP and cone-beam

computed tomography at different spatial resolutions and pixel/voxel size in permanent teeth, finding no significant differences between these systems. This may mean that technological evolution does not influence the accuracy in detecting these lesions.<sup>1,8-10,12</sup>

The low sensitivity and high specificity found in the present study are consistent with previous studies, such as Abogazalah *et al.*,<sup>15</sup> who studied CCD sensor. This system showed a sensitivity of 0.5 and specificity of 0.64 in the detection of non-cavitated carious lesions. Furthermore, Pontual *et al.*,<sup>9</sup> compared the sensitivity and specificity of three PSP systems against a conventional film in detecting enamel carious lesions and also found low sensitivity values (0.14 to 0.16) and high specificity values (0.89-0.94). An important factor for the detection of carious lesions is observer's experience,<sup>16</sup> which may explain the diversity of results found in the literature. Most experts, in a first visual inspection, focus on relevant areas, while inexperienced observers overestimate some details. In addition, experienced observers correctly detect the absence of disease, and in less time, than the inexperienced ones.<sup>16</sup>

The high PPV for both systems demonstrate the high probability of diagnosing carious lesions adequately. The importance of predictive values lies in their relationship with the prevalence of the disease. A disease with high prevalence usually has a high PPV and low NPV.<sup>17</sup> In contrast, Dehghani *et al.*,<sup>1</sup> found high NPV, for both CCD and PSP, for cavitated and non-cavitated surfaces, in an Iranian population. The information provided by the predictive values is important for routine clinical practice and decision making.<sup>17</sup> It means that when a coronary

radiolucency is detected in a high prevalence country it is predictive of a carious lesion, unlike in a low prevalence country. This information is important in the Latin American context, where a high prevalence of dental caries has been found.<sup>18</sup>

Regarding the value of the area under the ROC curve (Az value), this is directly related to the sensitivity and specificity of the tests. These values should not be used to compare digital radiography systems, because sensitivity and specificity do not depend on disease prevalence.<sup>17</sup> Considering the Swets' criteria, both systems showed a low accuracy in detecting proximal non-cavitated carious lesions in the present study.<sup>14</sup> Similar results have been found in previous studies.<sup>10,19</sup>

Abogazalah *et al.*,<sup>15</sup> studied non-cavitated surfaces with CCD and found a Az value of 0.5. Krzyżostaniak *et al.*,<sup>19</sup> evaluated carious lesions of posterior teeth without cavitation with Az values for PSP of 0.65, conventional film 0.66, and CBCT 0.63. Moreover, Li *et al.*,<sup>10</sup> evaluated four PSP systems at different resolutions, obtaining Az values between 0.60 and 0.74. The discrepancy of these values may be due to the condition of the teeth evaluated. While in the present study and Krzyżostaniak *et al.*,<sup>19</sup> it was specified that the teeth evaluated had no cavitation, Li *et al.*,<sup>10</sup> did not specify the condition of the teeth studied. This lack of information does not allow for the comparison of results. On the other hand, Şenel *et al.*,<sup>8</sup> studied posterior teeth obtaining the following Az values: conventional film (0.83), CCD (0.86), PSP (0.82) and CBCT (0.88).

These results are numerically superior to those of the present study because the teeth studied were cavitated. Thus, the greater the depth of the carious lesion, the greater is the accuracy of detecting them.

The discrepancy in the results of the present study with other studies could also be due to the fact that the technique used for the histological study was not the same and it was not performed by the same researcher. Therefore, this procedure was not standardized in all the investigations among themselves, resulting in various analyses on the detection of proximal carious lesions.

Radiographs detect mineral loss from 40% upwards.<sup>2</sup> With increased mineral loss, the ability to detect it radiographically increases, resulting in a greater agreement in caries detection. Ömen *et al.*,<sup>20</sup> studied the relationship

between the depth of the carious lesion and the amount of calcium loss measured with stereomicroscope (SM). They reported that calcium loss was slow in the early hours, but with more time, calcium loss increased and thus, accuracy in detecting carious lesions increased too. This is why Şenel *et al.*,<sup>8</sup> found Az values numerically superior to those found in the present investigation, in which all surfaces studied were sound or early visible changes clinically detected.<sup>21</sup>

The difference between enamel and dentin carious lesion lies in the composition of these tissues. Enamel is 88% composed of minerals, whereas dentin has only 50%.<sup>22</sup> X-rays detect carious lesion due to the mineral loss in enamel and dentin, which becomes evident when mineral loss is enough to generate contrast between adjacent sound tissues. Furthermore, caries detection is influenced by teeth morphology and bucco-lingual width.<sup>22</sup> In addition, enamel remineralization can arrest carious lesion in its outer shell, however, dentin has already lost its collagen matrix.<sup>23</sup> Therefore, in the present study, a small number of non-cavitated carious lesions were detected but according to histology they were deeper.

Considering the previously mentioned studies, it can be argued that despite the advances in technology that allow for better viewing of digital images, no greater accuracy in detecting carious lesions between CCD and PSP has been shown. Thus, another complementary technique for detecting carious lesions is needed. Dental caries is the most prevalent disease in the oral cavity and it is known that, in less than 2 years, a carious lesion becomes clinically visible.<sup>23</sup>

Intraoral radiology helps in the detection of carious lesions and is a complement to visual inspection and can determine the severity of the proximal lesion with or without cavity.<sup>21,24</sup> Diagnosis accuracy improves when a validated inspection technique is applied,<sup>25</sup> with the ICDAS-II system being a good example. In her research of validation system for the detection of proximal carious lesions in enamel with visual inspection (ICDAS-II) Dulanto found the following: 0.6 sensitivity, 0.7 specificity and 0.71 Az value.<sup>26</sup> These results are numerically higher than those found in the present study for CCD and PSP. It has been reported that temporary tooth separation allows a direct assessment of proximal cavitation detected by radiography.<sup>27</sup>

It has been shown that the sensitivity values of visual methods for detecting carious lesions in permanent dentition range from 0.27 to 0.77,<sup>28</sup> where the lower values correspond to non-cavitated carious lesions. Bitewing radiography is important to detect non-cavitated carious lesions on proximal surfaces and to determine lesion depth when there is an adjacent tooth that does not allow visual detection.<sup>27,29</sup>

Kajan *et al.*,<sup>30</sup> found that the application of sharpening with magnification 1:3 in PSP images improved diagnostic accuracy in the detection of non-cavitated approximal dental caries. So, in this digital era, more research about the accuracy of different digital systems with these variables is necessary to improve knowledge of dental caries detection. The presence of occlusal carious lesions in the specimens led to the loss of potential samples, so the sample size was

reduced. It is recommended that future studies include only specimens without occlusal carious lesion.

Although the detection of proximal carious lesions depends on the mesiodistal coronary width, the position of the teeth in the study unit also influences the detection of these lesions. This is why it is recommended that in future investigations the position and orientation of the teeth be standardized so the perpendicularity of the incident x-ray beam is guaranteed.

## CONCLUSION.

Despite the limitations of the present study, both CCD XIOS XG Sirona® and PSP VistaScan DürrDental® systems showed a high ability to detect sound surfaces, but a low accuracy to detect proximal carious lesions, without significant differences found between them.

## REFERENCES.

1. Dehghani M, Barzegari R, Tabatabai H, Ghanea S. Diagnostic Value of Conventional and Digital Radiography for Detection of Cavitated and Non-Cavitated Proximal Caries. *J Dent.* 2017;14(1):21–30.
2. White SC, Pharoah MJ. *Oral Radiology: Principles and Interpretation.* 7th Ed. Canada: Mosby/Elsevier; 2014.
3. Isaacson KG, Thom AR, Attack NE, Horner K, Whites E. *Guidelines for the Use of Radiographs in Clinical Orthodontics.* 4th Ed. London: British Orthodontic Society; 2015.
4. Kidd E, Fejerskov O. Changing concepts in cariology: forty years on. *Dent Update.* 2013;40(4):277–86.
5. Manton DJ. Diagnosis of the early carious lesion. *Aust Dent J.* 2013;58(Suppl 1):35–9.
6. Boeddinghaus R, Whyte A. Trends in maxillofacial imaging. *Clin Radiol.* 2018;73(1):4–18.
7. Abogazalah N, Ando M. Alternative methods to visual and radiographic examinations for approximal caries detection. *J Oral Sci.* 2017;59(3):315–22.
8. Senel B, Kamburoglu K, Uçok O, Yüksel SP, Ozen T, Avsever H. Diagnostic accuracy of different imaging modalities in detection of proximal caries. *Dentomaxillofac Radiol.* 2010;39(8):501–11.
9. Pontual AA, de Melo DP, de Almeida SM, Bóscolo FN, Haiter Neto F. Comparison of digital systems and conventional dental film for the detection of approximal enamel caries. *Dentomaxillofac Radiol.* 2010;39(7):431–6.
10. Li G, Berkhout WE, Sanderink GC, Martins M, van der Stelt PF. Detection of in vitro proximal caries in storage phosphor plate radiographs scanned with different resolutions. *Dentomaxillofac Radiol.* 2008;37(6):325–9.
11. Dikmen B. ICDAS II Criteria (International Caries Detection and Assessment System). *J Istanbul Univ Fac Dent.* 2015;49(3):63–72.
12. Abesi F, Mirshekar A, Moudi E, Seyedmajidi M, Haghanifar S, Haghghat N, Bijani A. Diagnostic accuracy of digital and conventional radiography in the detection of non-cavitated approximal dental caries. *Iran J Radiol.* 2012;9(1):17–21.
13. McHugh ML. Interrater reliability: the kappa statistic. *Biochem Med.* 2012;22(3):276–82.
14. Swets JA. Measuring the accuracy of diagnostic systems. *Science.* 1988;240(4857):1285–93.
15. Abogazalah N, Eckert GJ, Ando M. In vitro performance of near infrared light transillumination at 780-nm and digital radiography for detection of non-cavitated approximal caries. *J Dent.* 2017;63:44–50.
16. Cooper L, Gale A, Darker I, Toms A, Saada J. Radiology image perception and observer performance: how does expertise and clinical information alter interpretation? Stroke detection explored through eye-tracking. 1a Ed. Argentina: Medical Imaging; 2009.
17. Ruiz de Adana R. Eficacia de una prueba diagnóstica: parámetros utilizados en el estudio de un test. *JANO.* 2009;1736:30–2.
18. Martins S, Álvarez E, Abanto J, Cabrera A, López RA, Masoli C, Echevarría SA, Mongelos MG, Guerra ME, Amado AR. Epidemiología de la caries dental en america latina. *Rev Odontopediatr Latinoam.* 2014;4(2):13–8.
19. Krzyżostaniak J, Kulczyk T, Czarnecka B, Surdacka A. A comparative study of the diagnostic accuracy of cone beam computed tomography and intraoral radiographic modalities for the detection of noncavitated caries. *Clin Oral Investig.* 2015;19(3):667–72.
20. Onem E, Baksi BG, Sen BH, Sögüt O, Mert A. Diagnostic accuracy of proximal enamel subsurface demineralization and its relationship with calcium loss and lesion depth. *Dentomaxillofac Radiol.* 2012;41(4):285–93.
21. Gomez J. Detection and diagnosis of the early caries lesion. *BMC Oral Health.* 2015;15(Suppl 1):S3.
22. Eli I, Weiss EI, Tzohar A, Littner MM, Gelernter I, Kaffe I. Interpretation of bitewing radiographs. Part 1. Evaluation of the presence of approximal lesions. *J Dent.* 1966;24(6):379–83.
23. Takahashi N, Nyvad B. Ecological Hypothesis of Dentin and Root Caries. *Caries Res.* 2016;50(4):422–31.
24. Ferreira Zandoná A, Santiago E, Eckert GJ, Katz BP, Pereira de Oliveira S, Capin OR, Mau M, Zero DT. The natural history



- of dental caries lesions: a 4-year observational study. *J Dent Res.* 2012;91(9):841–6.
25. Gimenez T, Piovesan C, Braga MM, Raggio DP, Deery C, Ricketts DN, Ekstrand KR, Mendes FM. Visual Inspection for Caries Detection: A Systematic Review and Meta-analysis. *J Dent Res.* 2015;94(7):894–904.
26. Dulanto JA. Validación histológica in-vitro de ICDAS-II y MICRO-CT para la detección de lesiones de caries proximales y oclusales (Tesis) Madrid: Universidad Complutense de Madrid; 2015.
27. Freitas LA, Santos MT, Guaré RO, Lussi A, Diniz MB. Association Between Visual Inspection, Caries Activity Status, and Radiography with Treatment Decisions on Approximal Caries in Primary Molars. *Pediatr Dent.* 2016;38(2):140–7.
28. Hoskin ER, Keenan AV. Can we trust visual methods alone for detecting caries in teeth? *Evid Based Dent.* 2016;17(2):41–2.
29. Wenzel A. Radiographic display of carious lesions and cavitation in approximal surfaces: Advantages and drawbacks of conventional and advanced modalities. *Acta Odontol Scand.* 2014;72(4):251–64.
30. Kajan ZD, Tayefeh Davaloo R, Tavangar M, Valizade F. The effects of noise reduction, sharpening, enhancement, and image magnification on diagnostic accuracy of a photostimulable phosphor system in the detection of non-cavitated approximal dental caries. *Imaging Sci Dent.* 2015;45(2):81–7.